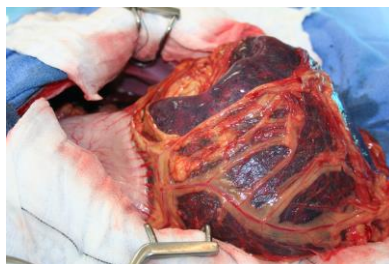



# **The Acute Abdomen Mini Series**

## **Session One: Managing a GDV in Practice**

Nicola Kulendra BVetMed (Hons) MVetMed CertVDI  
DECVS FHEA MRCVS  
European Specialist in Small Animal Surgery



## ***Gastric Dilatation and Volvulus***

Gastric dilatation and volvulus (GDV) is characterised by accumulation of gas within the stomach, rotation of the stomach, failure of eructation and pyloric emptying, increased gastric pressure and shock. It can be acute or more rarely can be chronic; acute cases can be rapidly fatal. It is common in deep chested dogs and the risk of a large or giant breed dog developing it in their lifetime has been reported to be 21 to 24%. Rapid diagnosis, stabilisation and surgical management can lead to a good prognosis for these dogs.

### **Aetiology**

Although the exact aetiology is unknown, several predisposing factors have been identified:

- Large and giant breeds, possibly familial tendencies
- Deep chested dogs (increased thoracic depth-to-width ratios)
- Diet and feeding
  - Diets composed of particles >30 mm in diameter reduce the risk of GDV
  - Dry diets are a potential risk factor
  - Feeding once daily; rapid eating leads to aerophagia which is a risk factor
- Nervous dogs more likely to develop GDV
- Dogs having a stressful event kennels/car journey
- Nasal mites leads to aerophagia
- Underlying inflammatory bowel disease (IBD)

### **Pathophysiology**

The current understanding is that dilation precedes volvulus leading to a stomach filled with fluid or air, which has rotated about the long axis of the oesophagus. The gas can either accumulate because of aerophagia, fermentation of gastric contents or less likely, diffusion from the blood stream. Distension of the stomach and rotation can cause venous outflow obstruction and a significant reduction in gastric oxygen tension. This can cause necrosis of the gastric mucosa, or in severe cases, all layers of the stomach wall.

Compression of the caudal vena cava can cause a decrease in venous return to the heart and contribute to an obstructive shock. In addition, myocardial ischemia, arrhythmias and the production of myocardial depressant factor can cause cardiogenic shock.

There is reduction in expansion of the thorax as the increase in abdominal pressure can affect movement of the diaphragm.

Translocation of bacteria across the gastrointestinal tract can result due to ischaemia and impaired defence mechanisms in addition to reduced lymphatic drainage. Endotoxaemia may lead to septic shock in some dogs.

## **Clinical presentation**

### *Signalement*

GDV predominantly occurs in large and giant breed dogs. Certain breeds such as Great Danes, German Shepherd dogs and Standard Poodles are at increased risk. Theoretically, it can affect any breed dog, even Dachshunds and Jack Russell Terriers! Dogs tend to be middle aged or older and there is no sex-predilection.

### *History*

The owners may report a progressively distending and tympanic abdomen, non-productive retching, hypersalivation, tachypnoea and restlessness. The condition is painful and some dogs adopt the “praying” position. As the disease and severity progresses, the dog may collapse.

### *Physical Examination*

This generally reveals a variably distended abdomen which is usually tympanic. Clinical signs of shock, such as weak pulses, tachycardia, prolonged capillary refill time and pale mucous membranes may be present. Occasionally, dogs may present with brick red mucous membranes if they are in septic shock. Tachypnoea and dyspnoea may also be present.

### *Clinico-pathologic changes*

On haematology there may be haemoconcentration, leukopenia or leucocytosis (depending on the stage of the disease). There may be thrombocytopaenia if the animal presents in Disseminated Intravascular Coagulation (DIC). Biochemical abnormalities may include elevated liver enzymes, hyperbilirubinaemia, elevated blood urea nitrogen and hypokalaemia. If there is the facility to measure lactate it may be high.

## **Pre-operative management**

At presentation, the goal is to stabilise the patient’s condition as much as possible, to facilitate anaesthesia. Prolonged stabilisation is not recommended because continued gastric and splenic ischaemia may occur without surgical correction. The timing of surgery should be as soon as the animal is sufficiently stable for anaesthesia, during the “window of opportunity”.

### *Fluid therapy*

Stabilisation of the cardiovascular system is the first priority. Large bore intravenous (IV) catheters should be placed in both cephalic veins to allow a large amount of fluids to be administered quickly. Using the saphenous veins or venous access caudal to the diaphragm is not recommended in the first instance because of obstruction of the caudal vena cava by the stomach.

Intravenous isotonic crystalloids (Hartmanns or 0.9% NaCl) are recommended as there is no known benefit of colloids for fluid resuscitation. A "shock rate" of 60 to 90ml/kg can be split into a quarter (e.g. 15 ml/kg) or a third (20ml/kg) and given over a 15 minute period. At the end of this 15 minutes, the dog can be reassessed (checking pulse quality, heart rate etc.) and if still unstable another quarter or half dose can be given. As most patients are large dogs, high volumes are often needed. Most dogs are healthy prior to presentation therefore there is minimal risk of fluid overload as a result of aggressive fluid therapy.

### *Analgesia*

This is a very uncomfortable condition and so analgesia should be provided early in the stabilisation process. A pure  $\mu$ -agonist such as methadone (0.1-0.2mg/kg) is recommended. Other  $\mu$ -agonists such as morphine is controversial as it can cause nausea and induce emesis, however, if there is no other alternative then it is appropriate. Partial  $\mu$ -agonists such as buprenorphine do not provide as much analgesia but can be used if there is no alternative.

### *Radiography*

The stomach can twist in many directions and to different degrees and so the appearance can vary. Most commonly, the greater curvature rotates clockwise (when viewed from caudal to cranial) to lie on the ventral abdominal wall. The pylorus moves cranially, to the left and dorsally.

The major radiographic finding is gas and fluid distension of the stomach. The main differential diagnosis is gastric dilatation and identifying the pylorus is essential to interpreting the radiographs. The right lateral radiograph is the most useful. Compartmentalisation is the key to diagnosis; this is a soft tissue band that projects into or across the lumen of the stomach. A right lateral radiograph with a large gas filled viscous but no compartmentalisation is more likely to be gastric dilation.

If there is perforation of the stomach, pneumoperitoneum may be apparent. If there is a haemoabdomen caused by rupture of the short gastric arteries or spleen, there may be loss of serosal detail.

Other conditions to rule out are abdominal distension caused by fluid such as haemoabdomen, septic peritonitis or ascites, abdominal masses and splenic torsion.

### *Gastric decompression*

Draining air from the stomach will help improve cardiovascular and respiratory function. The best way to perform decompression is by passing a well lubricated orogastric tube. The dog may be sedated enough from the methadone to perform the procedure; another 0.1-0.2mg/kg of methadone can provide more sedation. Alternatively, addition a benzodiazepine (e.g. midazolam 0.2mg/kg) can provide additional sedation.

The tube is measured to the last rib, and passed gently down the oesophagus into the stomach. A roll of bandage material (e.g. Vetwrap) will help keep the mouth open and allow the tube to pass down the centre of the tube.

Sometimes the nature of the volvulus will not allow the tube to pass; gentle twisting of the tube can help in some cases but take care not to force it. Once in the stomach gastric contents will flow so keep a bucket on the floor ready to catch the fluid.

If orogastric intubation is not possible, percutaneous gastrocentesis can be performed. A large-bore (14G) needle or over-the-needle IV catheter placed in the right or left paracostal space at the site of greatest tympany. The area is clipped and scrubbed prior to needle insertion.

If it is not possible to decompress the stomach, anaesthesia and surgery should be performed. Although decompression is of benefit, spending prolonged periods of time attempting either procedure is suboptimal as there is often a window of opportunity to perform anaesthesia after stabilisation before the animals deteriorate again. It can be easier to pass a stomach tube once the animals are anaesthetised.

### **Anaesthetic considerations**

Restoration of cardiovascular and pulmonary functions is the primary goal prior to surgery, however this may not always be achieved. Patients therefore often enter the anaesthetic period with cardiopulmonary compromise. Cardiac arrhythmias, myocardial and pulmonary depression, and acid-base and electrolyte disturbances can be present and may be exacerbated prior to, during and after anaesthesia.

A thorough review of anaesthetic agents is not going to be provided, just some brief guidelines. Drugs with known arrhythmogenic potential and that produce concurrent hypotension such as halothane,  $\alpha_2$  agonists (e.g. medetomidine) and thiopentone should be avoided where possible. Propofol can cause significant hypotension and so should be used cautiously at low doses given slowly to effect.

Cardiovascular sparing drugs such as opioids and benzodiazepines can be used as a premedication and so will reduce the dose of propofol required. If available, etomidate or alfaxalone could be used instead of propofol for induction. Ketamine can also be added to the anaesthetic protocol because of its positive effect on the cardiovascular system.

Pre-oxygenation is recommended prior to induction to reduce the likelihood of desaturation and hypoxia if apnoea occurs. Intermittent positive pressure ventilation may be necessary during the initial anaesthetic period to ensure adequate ventilation until the stomach is surgically decompressed.

Anaesthesia should be maintained with an inhalation agent such as sevoflurane or isoflurane. Nitrous oxide reduces the requirements for inhalation agents, but should not be used until permanent gastric decompression has been achieved.

If available, an electrocardiogram (ECG) is used to monitor for arrhythmias. Transient ventricular arrhythmias are also seen during anaesthesia and most commonly cease after surgery. There are certain guidelines that define when to treat arrhythmias, such as hypotension, persistent ventricular tachycardia, multiform ventricular complexes, or superimposition of the QRS wave on the T wave. Lidocaine is used in these cases.

Perioperative antibiotics such as cefuroxime (20mg/kg) or co-amoxiclav (20mg/kg) can be given 30 minutes before the first incision. If there is any gastric necrosis or rupture, they can be maintained for 5 to 10 days after the surgery but otherwise it is not necessary to continue them post-operatively.

### **Surgical management**

The goals of surgery include:

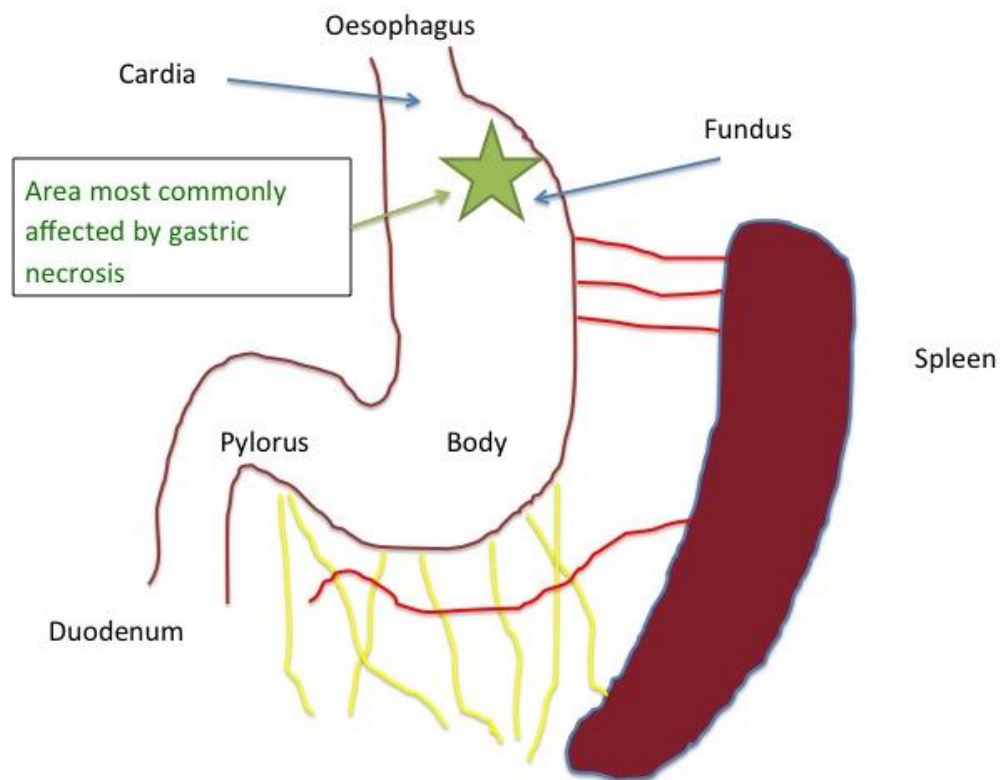
- Further decompression
- Correction of gastric malpositioning
- Assessment of gastric and splenic viability
- Prevention of recurrence

Exploratory laparotomy is performed via a midline incision extending from the xiphoid to just cranial to the pubis. A large incision facilitates the rest of the surgery. Balfour retractors are very helpful. If it was not possible to place an orogastric tube earlier, one can be manipulated into the stomach via the laparotomy site. If the stomach is still very dilated, decompressing it with a large gauge needle will help with the de-rotation; care is taken to avoid spillage of gastric contents into the rest of the abdomen. Gastric lavage is performed using 7–10 ml/kg of water, which will help to remove most of the liquid and solid gastric contents.

Derotation of the stomach is performed; when looking from the rear of the animal, both clockwise (up to 360 degrees) and anti-clockwise (up to 90 degrees) rotations are possible. Clockwise is more common; in these dogs, the greater omentum will be visible stretched across the surface of the stomach. The pylorus is identified and the stomach is manipulated back into position. This is facilitated by having a decompressed stomach.

The short gastric arteries and veins are often ruptured and can produce a low volume haemoabdomen. The gastric wall is inspected to assess viability; this includes making a window in the greater omentum and examining the dorsal aspect of the stomach. Gastric necrosis has been reported in approximately 12% of cases and most commonly occurs along the greater curvature of the fundus and body of the stomach (see figure below).

Necrotic tissue may appear black or grey-green on the serosal surface, often feels thin and may be friable, necrotic tissue will not bleed when cut. Mucosa is often necrotic and does not need to be removed.



Necrotic gastric wall should be removed. Previously invagination where the necrotic area was inverted into the gastric lumen to allow autodigestion is not recommended because of the risk of the continued release of inflammatory cytokines from the necrotic tissue, risk of sepsis and gastric obstruction.

Removing the necrotic tissue can be performed either by use of sutures or staples. When assessing how much tissue to remove, there has to be enough of the cardia to be able to suture around the large bore orogastric tube; if the entire cardia and lower oesophageal sphincter is necrotic, there is a poor prognosis and the animal is euthanized.

To perform a partial gastrectomy, the stomach is isolated with moistened laparotomy sponges and stay sutures are placed in the surrounding healthy stomach. The necrotic portion is resected back to normal bleeding tissue using metzenbaum scissors. A simple continuous pattern of 2 Metric PDS is placed in the mucosa and submucosa layer. The muscularis and serosa layer is sutured separately with a simple continuous pattern using the 2M PDS.

Stapling is easier and quicker; the Gastrointestinal Anastomosis (GIA) stapler places 2 rows of staples and cuts between the central two lines and thus minimises leakage. Oversewing with a simple continuous PDS suture is not essential but can be performed if there is any doubt as to the integrity of the staple line.

The spleen should also be assessed for torsion and viability. Often the spleen is enlarged, turgid and a dark purple colour but returns to a more normal colour shortly after being replaced. A pulse should be felt in the splenic artery. If no pulse is felt or if there is splenic torsion, a total splenectomy is performed.

### *Gastropexy*

Gastropexy is necessary to prevent recurrence to create a permanent adhesion between the pyloric antrum and the right abdominal wall. There are many different gastropexy techniques, including incisional, belt-loop, circumcostal and tube gastropexy. It is important to perform the gastropexy on the right side of the abdomen so that the pylorus is immobilised; if a left sided gastropexy is performed, the pylorus can still rotate around the gastropexy site. The decision as to which to perform is at the surgeons' discretion. As the incisional gastropexy is the easiest to perform, it is the authors' choice and the technique will be described below. The incorporating gastropexy involves suturing the stomach to the linea alba when closing the abdomen. Because the pylorus is located at the centre of the abdomen, volvulus can still occur with this technique. In addition, in future laparotomies, the stomach may inadvertently be entered when opening the abdomen.

To perform an incisional gastropexy, the Balfour retractors are removed and Allis tissue forceps are applied to the right body wall and the stomach is held up by an assistant. A 4 to 5 cm incision is made in the seromuscular layer of the pyloric antrum, between the lesser and greater omentum. An incision of the same length is made in the right body wall through the transverse abdominus muscle layer, approximately halfway between the dorsal and ventral aspect of the body wall. The cranial edge of the stomach and body wall is sutured using 3.5M PDS in a simple continuous pattern, and then the same is repeated on the caudal edges.

### **Post-operative care**

Intravenous fluids and opioid analgesia are continued for the first 24 to 48 hours after surgery. If aggressive fluid therapy has been used, monitoring the electrolytes is advised as hypokalaemia can develop. Food and water can be offered as soon as the dog has recovered from the anaesthesia. Gastroprotetant drugs such as omeprazole (1mg/kg SID) or ranitidine (2mg/kg BID) can be given if there is injury to the mucosa. The perioperative antibiotics should be continued if partial gastrectomy was performed.

**Prognosis**

Recent studies have shown that the mortality rate is lower than previously thought (15-24%). Gastric necrosis and need for gastrectomy and splenectomy were found to be negatively associated with outcome in one study. Another study found that high initial lactate or minimal change in lactate after fluid therapy is negatively associated with outcome.

**Prophylactic gastropexy**

This can be performed in animals thought to be at-risk. It is not associated with many complications as the animals are good anaesthetic candidates. It can either be performed alone or in combination with ovariohysterectomy, splenectomy or other abdominal procedures. It can also be performed laparoscopically. Dogs having gastric dilation without volvulus should have a gastropexy performed when stable because of the risk of subsequently developing a GDV.