

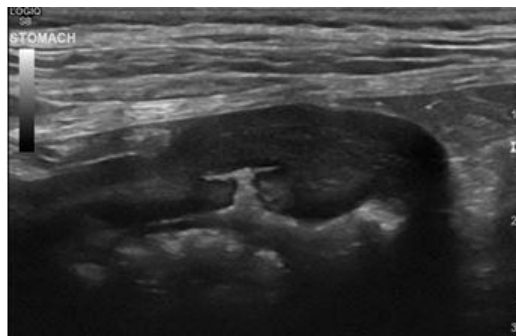


Abdominal Ultrasound Level 2 Mini Series

Session One: Pancreas, Adrenals & Prostate

Sally Birch BVSc (hons) CertAVP Dip ECVDI
MRCVS

European and RCVS Specialist in Veterinary
Diagnostic Imaging



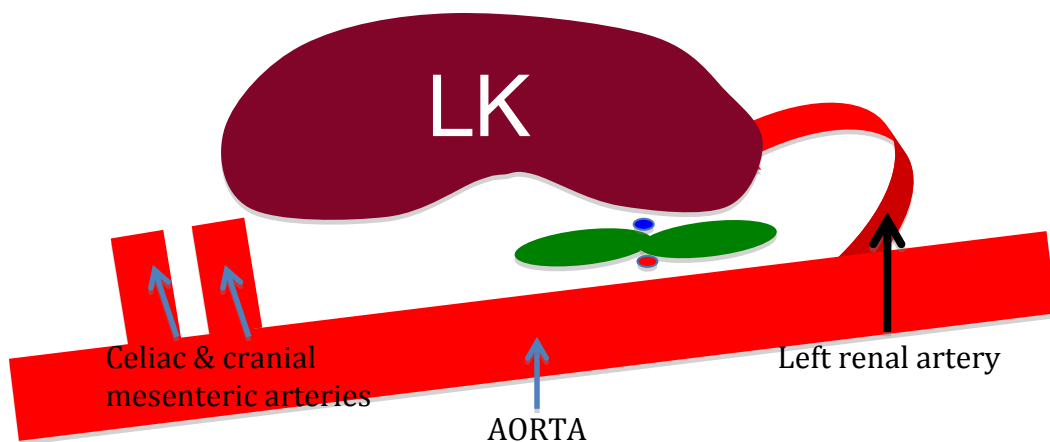
The Adrenal Glands

Locating the Adrenal Glands

The adrenal glands are retroperitoneal organs that in dogs are located medial to the cranial pole of each kidney. In cats, the adrenal glands (particularly the right adrenal) are often located slightly cranial to their respective kidney.

Landmarks for the left adrenal: left kidney, left renal artery and cranial mesenteric and celiac arteries.

The cranial mesenteric and celiac arteries are the first arteries to arise from the abdominal aorta and are easily recognised because they branch off as a pair, very close together. The adrenal gland (shown in green below) is usually found in the area bordered by these two vessels cranially, the left renal artery (which forms a 'hook') caudally, the aorta medially and the left kidney laterally.

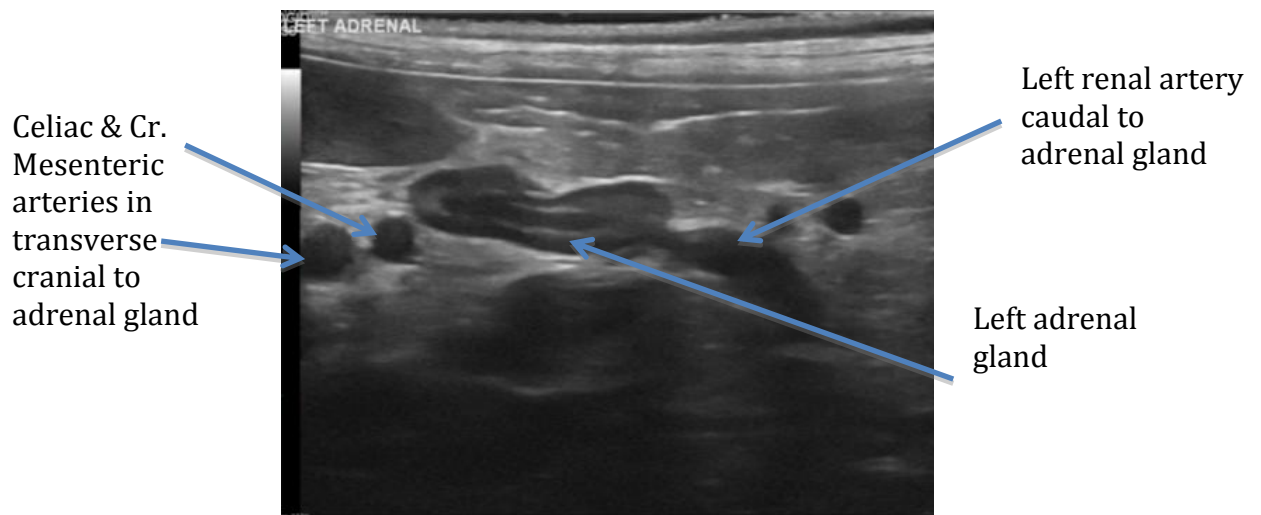


Schematic showing the landmarks for the left adrenal gland (green) Note the dots dorsal and ventral to the centre of the gland. These represent the phrenicoabdominal artery and vein respectively in transverse. These vessels also aid in the identification of the adrenal gland.

The positioning of the animal depends on the preference of the sonographer. My preference is to have the animal in right lateral recumbency with the probe on the left lateral abdomen.

Steps to find the left adrenal gland:

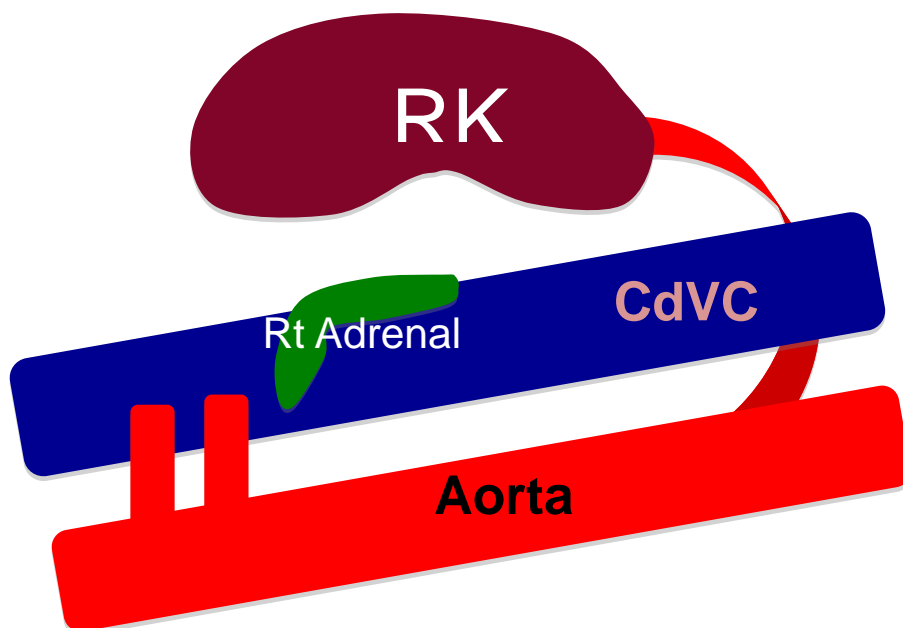
1. With the animal in right lateral recumbency, locate the left kidney and rotate the transducer such that you obtain a longitudinal image of the kidney. In most animals this means that your transducer will be caudal to the last rib and positioned over the dorsal aspect of the abdomen.
2. Now, slowly fan medially maintaining reasonable pressure with your transducer. You should start to see the hook of the left renal artery come into view and two round anechoic structures should also start to appear more cranially. The round structures represent the coeliac and cranial mesenteric arteries in transverse section – if in doubt, follow these to the aorta to confirm their origin.



3. As these vessels come into view, you should search the area between them and the left kidney. The left adrenal gland is often at least partly already in view at this point. Be prepared to rotate the probe clockwise by about 10-15 degrees to obtain a longitudinal image of the adrenal gland. Note that it is quite common not to see the kidney in the optimised image of the left adrenal gland.

The adrenal glands are normally hypoechoic relative to the surrounding fat. In many dogs, a hypoechoic cortex and a hyperechoic medulla can be appreciated. This is the reverse of the corticomedullary echogenicity identified in the kidney. It is less common to appreciate the difference in echogenicity of the feline adrenal cortex and the medulla. With regards to shape, the left canine adrenal gland is often described as being 'dumbbell' or 'peanut-shaped' in the longitudinal plane. This shape is usually most obvious in smaller breeds of dog since in large breeds, the adrenal is often dorsoventrally flattened and may mimic a section through a blood vessel. If there is uncertainty, Colour Doppler can be used to differentiate between a blood vessel (flow present) and the adrenal gland (no flow within the gland although flow above and/or below the centre of the gland may be visible due to the presence of the phrenicoabdominal artery and vein). In cats, the adrenal glands are typically ovoid, hypoechoic structures.

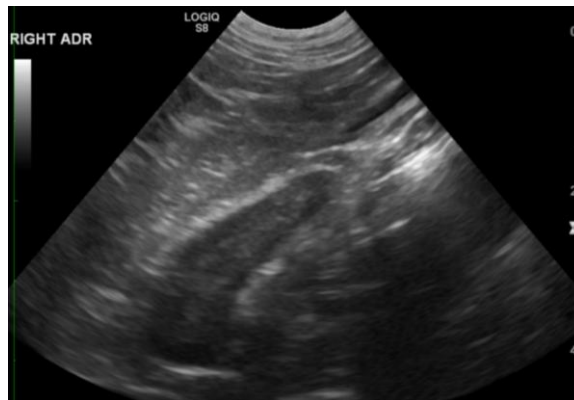
Landmarks for the right adrenal: right kidney and caudal vena cava (CVC)



Schematic showing the landmarks for the right adrenal gland shown in green. The right phrenicoabdominal artery and vein also accompany the right adrenal gland however are not shown in this image.

Steps to find the right adrenal gland:

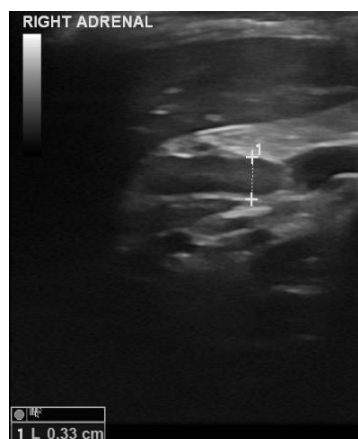
1. With the animal in left lateral recumbency, place the probe on the dorsal aspect of the right flank, just caudal to the last rib and direct the transducer cranially to locate the right kidney.
2. Once you have obtained a sagittal image of the kidney, fan slightly medially until the CVC appears. You may also see the aorta deep to the CVC. Adjust your transducer position until a longitudinal view of the CVC is obtained (the vessel should span the entire width of the field of view). As long as you are still at the level of the right kidney, do not worry if the right kidney does not remain in view at this point.
3. From the CVC, fan **very slowly** dorsolateral taking care not to rotate the transducer. The right adrenal in the dog lies immediately adjacent to the CVC and if you fan too quickly or your movements are too large, you may miss the gland altogether.



The right adrenal is typically described as being 'boomerang-shaped' in the dog. In the cat, the right adrenal is ovoid and often located slightly cranial to the right kidney at a short distance from the CVC.

Normal Adrenal Gland size

Many studies have tried to ascertain the normal size range for the canine adrenal gland. Looking at the results of these studies, it is clear that there is a substantial range in normal adrenal gland size, which is predominantly dependent on the size of the dog. The most reliable and accurate means of measuring the adrenal gland is to measure the dorsoventral diameter of the caudal pole of each adrenal as shown (caudal is to the right of the image):



Traditionally, the most widely-accepted cut-off value has been 0.74cm regardless of bodyweight. This value is reported to have a sensitivity of 77% and a specificity of between 80-91% for the detection of adrenal gland enlargement due to hyperadrenocorticism. Naturally however, there will be a population of dogs with normal adrenal glands that are larger than this. A more recent study has attempted to correlate adrenal gland size and bodyweight and has suggested the following cut-off values:

<10kg: ≤0.54cm
10-30kg: ≤0.68cm
>30kg: ≤0.80cm

The maximum transverse diameter of the normal adrenal gland in the cat has been reported to vary from 2.8 and 5.5mm in one study of 20 cats and 4.3 +/-0.3mm in a second study of 10 cats. The length of the normal feline adrenal gland is usually around 1cm. Mineralisation of the adrenal glands in cats is commonly observed and at present, is considered to be an incidental finding. Mineralisation may also be apparent on abdominal radiographs.

Diseases of the adrenal glands in dogs

Pituitary-dependent hyperadrenocorticism (HAC)

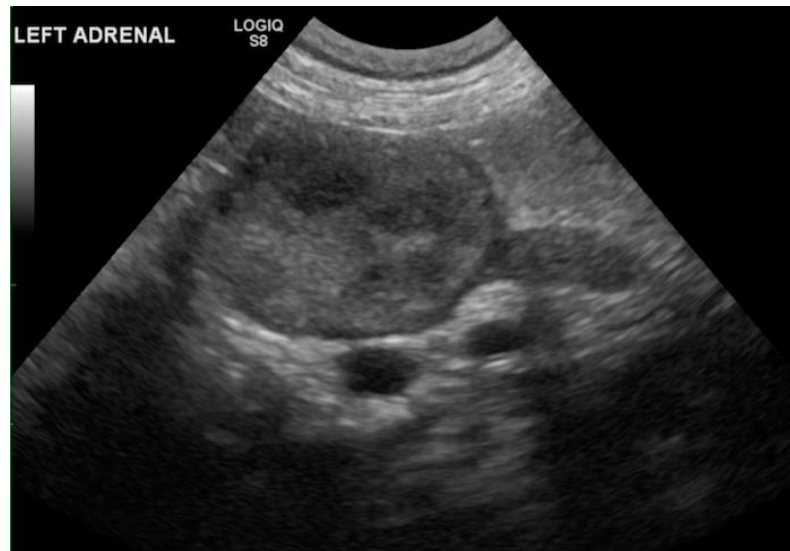
- Accounts for approximately 80% of cases of HAC
- Common in Poodles, Dachsunds, Beagles, Boxers, Boston Terriers and German Shepherds
- An over-production of ACTH (adrenocorticotrophic hormone) from a pituitary tumour (usually an adenoma) results in bilateral stimulation and symmetrical enlargement of the adrenal glands.
- The adrenal glands usually maintain a fairly normal shape and may appear slightly reduced in echogenicity, which can assist in their identification during the abdominal ultrasound exam.
- The liver may be uniformly enlarged and diffusely hyperechoic due to steroid hepatopathy
- There are however, various factors that can complicate interpretation:
 - Enlargement of the adrenal glands due to pituitary dependent HAC can be asymmetrical or unilateral (moderate to marked unilateral enlargement makes differentiation from primary or metastatic adrenal tumours difficult)
 - Adrenal glands can be normal in size in dogs with pituitary-dependent HAC and enlarged in dogs without adrenal disease (e.g. medical stress due to non-adrenal causes)
 - Cortical hyperplasia can be nodular. Hyperplastic nodules can rarely become quite large (>2cm diameter) and this must be differentiated from a tumour.
 - Adrenocortical adenomas, adenocarcinomas and pheochromocytomas can co-exist in an animal with pituitary-dependent adrenocorticism
 - Lymphoma can cause bilateral adrenomegaly
- Since ultrasound findings can be non-specific or even misleading, they should always be interpreted in conjunction with the clinical history and examination findings and with the results of laboratory tests.
- Trilostane, a 3 β -hydroxysteroid-dehydrogenase inhibitor, causes a reduction in cortisol production by the adrenal glands resulting in loss of negative feedback to the pituitary gland. This in turn causes increased ACTH secretion and hyperplasia of the adrenal glands. Ultrasound findings that have been reported in dogs on trilostane therapy and include adrenomegaly and prominent hypoechoic cortices.

Adrenal-dependent hyperadrenocorticism

- Accounts for approximately 20% of the cases of HAC
- The typical ultrasound picture is a nodule or mass in one adrenal gland and assuming the mass is functional, a reduction in the size of the contralateral gland due to atrophy. In some dogs, the contralateral gland may remain normal in size. One study has

suggested that adrenal-dependent HAC is more likely if there is adrenal asymmetry and the smaller of the two glands measures <5mm diameter.

- Adrenocortical neoplasia is reported more frequently in females and in large breeds of dog.
- Masses are usually round or ovoid and vary in echogenicity from being hypoechoic, heterogenous or hyperechoic.
- An adrenal mass or nodule causing HAC will be either a functional adenoma or adenocarcinoma. Note that not all adrenocortical adenomas and adenocarcinomas are functional. There are no pathognomic ultrasound features for either lesion and further differentials including nodular hyperplasia, pheochromocytoma and a metastatic nodule should also be considered. Concurrent pheochromocytomas and adenocarcinomas have been reported in the same adrenal gland.



Mass associated with the cranial pole of the left adrenal gland in a dog.

Pheochromocytomas

- Arise from the chromaffin cells of the adrenal medulla
- Cause the episodic release of excess catecholamines
- Around half are identified incidentally during abdominal ultrasound either because the clinical signs are non-specific or during investigation of another condition.
- Both pheochromocytomas and adrenal carcinomas can lead to hypertension hence this finding is not pathognomic for the former in the presence of a large adrenal mass.
- Cause vague and often episodic clinical signs such as weight loss, polydipsia/polyuria, weakness, pallor, arrhythmia, collapse, anorexia, vomiting, lethargy and panting.
- Only around 10% mineralise
- Can invade local structures including the caudal vena cava (often via the phrenicoabdominal and/or renal veins)
- Frequently metastasize particularly to the liver and lungs.

Unfortunately, it is not possible to determine the nature of an adrenal nodule or mass, based on its ultrasound appearance alone and a fine needle aspirate (FNA) or biopsy must be performed in order to obtain a definitive diagnosis. There are however, a few general guidelines that can help in the decision making process.

1. An adrenal nodule <1cm is non-specific.
2. An adrenal mass >4cm is more likely to be a malignant tumour the main differentials for which are adenocarcinoma and pheochromocytoma.
3. Metastatic disease to the adrenal glands is relatively common and can present as bilateral adrenal nodules. The main differentials are nodular hyperplasia or an early primary tumour.

4. A mineralised adrenal mass is more likely to be an adenoma or adenocarcinoma. Pheochromocytomas can mineralise but only do so infrequently. Mineralisation has been reported in nodular hyperplasia but is rare.
5. If invasion of local structures such as the kidney or caudal vena cava is present, an adrenal mass is almost certainly malignant (adenocarcinoma or pheochromocytoma).
6. Both adrenal adenocarcinomas and pheochromocytomas can rupture spontaneously and haemorrhage into the retroperitoneal space.

Incidental nodules and masses

- Differentials include nodular hyperplasia, adenoma/adenocarcinoma (functional, non-functional or sub-clinical), pheochromocytoma, metastasis and myelolipomas (fatty masses), the latter being occasionally present in the adrenal glands and appear as well-circumscribed hyperechoic nodules.
- Clinical history, examination and existing blood results should be reviewed for any evidence of a functional adrenal tumour. Options include testing for hypertension and loss of hypothalamic-pituitary-adrenal responsiveness to a low dose of dexamethasone, monitoring over time with serial ultrasound examinations and obtaining a tissue sample by either FNA or biopsy.

Small adrenal glands

Hypoadrenocorticism causes adrenal glands to be abnormally small (left <3.2mm; right <3mm). Other differentials that can also cause a reduction in adrenal size include exogenous steroid administration and mitotane therapy. Mitotane causes necrosis of the adrenal cortex and a reduction in size of the glands.

Sampling

Fine needle aspiration of the adrenal gland masses is an uncommon procedure. Even with a biopsy there is often insufficient material present to make a definitive diagnosis. If an unsuspected pheochromocytoma is accidentally sampled, possible consequences include paroxysmal hypertension and uncontrollable, cardiac arrhythmias and potentially fatal haemorrhage.

References

1. Grooters AM, Biller DS, Theisen SK, et al. Ultrasonographic characteristics of the adrenal glands in dogs with pituitary-dependent hyperadrenocorticism: comparison with normal dogs. *J Vet Intern Med* 1996;**10**:110-15.
2. Soulsby SN, Holland M, Hudson JA, Behrend EN. Ultrasonographic evaluation of adrenal gland size compared to body weight in normal dogs. *Vet Radiol Ultrasound* 2015;**56**(3):317-26.
3. Zimmer C, Horauf A, Reusch C. Ultrasonographic examination of the adrenal gland and evaluation of the hypophyseal-adrenal axis in 20 cats. *J Small Anim Pract* 2000;**41**:156-60.
4. Cartee RL, Finn-Bodner ST, Gray BW. Ultrasonography of the normal feline adrenal gland. *J Diagn Med Sonogr* 1993;**9**:327-30.
5. Benckroun G, De Fornel-Thibaud P, Rodriguez Pineiro MI, et al. Ultrasonography criteria for differentiating ACTH dependency from ACTH independency in 47 dogs with hyperadrenocorticism and equivocal adrenal asymmetry. *J Vet Intern Med* 2010;**24**:1077-85.
6. Gilson SD, Withrow SJ, Wheeler SL, et al. Pheochromocytoma in 50 dogs. *J Vet Intern Med* 1994;**8**:228-32.
7. Barthez PY, Marks SL, Woo J, et al. Pheochromocytoma in dogs: 61 cases (1984-1995). *J Vet Intern Med* 1997;**11**:272-8.
8. Wenger M, Mueller C, Kook PH, et al. Ultrasonographic evaluation of adrenal glands in dogs with primary hypoadrenocorticism or mimicking diseases. *Vet Rec* 2010;**167**:207-10.
9. Horauf A, Reusch C. Effects of mitotane therapy in dogs with pituitary-dependent Cushing Syndrome on the adrenal gland size- an ultrasonographic study. *Schweiz Arch Tierheilkd* 1999;**141**:239-45.
10. Mantis P, Lamb CR, Witt AL. Changes in ultrasonographic appearance of adrenal glands in dogs with pituitary-dependent hyperadrenocorticism treated with trilostane. *Vet Rad Ultrasound* 2003;**44**(6):682-5.

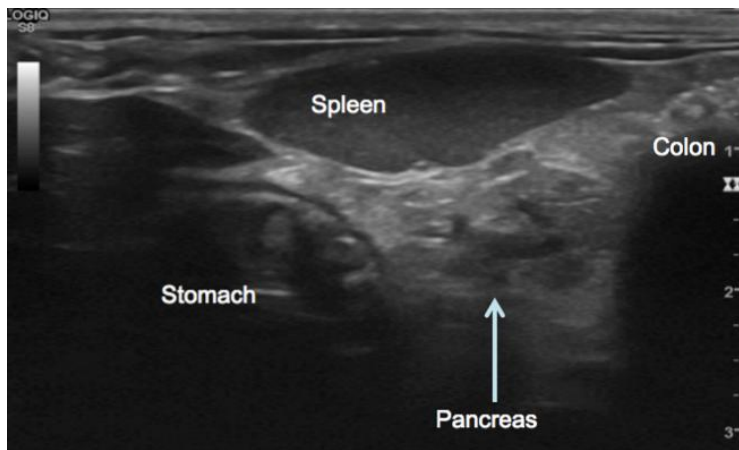
The Pancreas

Normal anatomy and appearance of the pancreas

The pancreas is made up of a left limb, a body and a right limb. The left limb is sandwiched between the greater curvature of the stomach cranially and the transverse colon caudally. The body of the pancreas is located immediately ventral to the portal vein at the porta hepatis. The right limb of the pancreas lies dorsomedial to the descending limb of the duodenum. The normal pancreas is usually slightly hypoechoic to surrounding fat and has a coarser echotexture than the spleen.

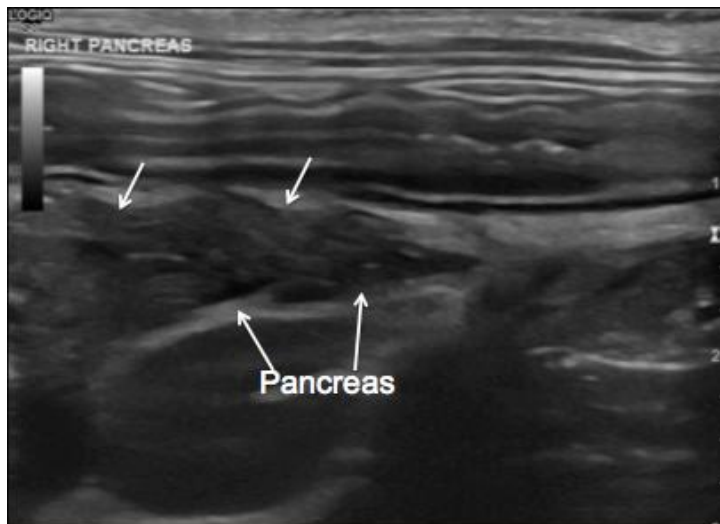
Finding the left limb of the pancreas

I prefer to locate the left limb of the pancreas with the animal in right lateral recumbency and the transducer placed on the left flank. A frequency around 8-15MHz is appropriate in most cases unless the dog is very large in which case it may be necessary to use a slightly lower frequency to improve depth of penetration of the ultrasound beam. The landmarks for the left pancreatic limb are the spleen, stomach and transverse colon. The splenic vein is sometimes visible deep to the left limb.



Finding the right limb of the pancreas

I normally start with the animal in left lateral recumbency and the transducer placed dorsally on the right flank. To find the right limb of the pancreas, start by finding the right kidney and then fan medially until the descending limb of the duodenum is visible. The duodenum can easily be recognised since it is the most superficial loop of intestine lying just ventral to the abdominal wall, slightly thicker than jejunal loops of intestine and follows a straight path along the right side of the abdomen. If in doubt, it can be followed cranially to confirm that it joins the pylorus. Once the duodenum is visible, fanning slightly dorsomedially should allow the right pancreatic limb to come into view. The pancreaticoduodenal vein is often visible running through the centre of the right limb of the pancreas in the dog, acts as a useful landmark and can be differentiated from the pancreatic duct by the presence of colour when Colour Doppler is used, indicating flow.



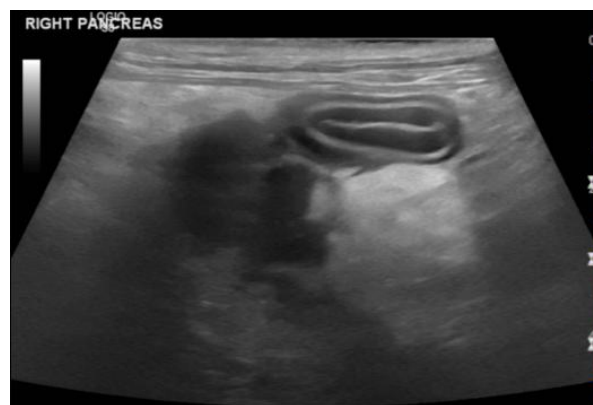Right limb of the pancreas in a dog

In dogs, right limb of the pancreas is easier to identify than the left limb. The thickness of the canine pancreas varies markedly from around 4mm to 1cm and greater. In cats, the left limb of the pancreas is larger (around 5-9mm thickness) and easier to identify than the right limb (around 3-6mm thickness). In cats, the pancreatic duct may be visible as an anechoic tubular structure with thin echogenic walls located centrally within the pancreas that travels the length of the left limb. The pancreatic duct increases in size with age in normal cats and measures between 0.4 and 2.5mm diameter. The duct may also be visible in the dog, albeit less commonly, particularly in the right limb and measures up to 1mm diameter.

Pathology of the Pancreas

Acute pancreatitis

Acute pancreatitis is more commonly diagnosed in dogs than in cats but is recognised in both species. Pancreatitis may affect either limb or the entire pancreas. The typical changes observed include a mass effect in the region of the pancreas, which may displace the duodenum laterally or transverse colon caudally depending on which part of the pancreas is affected. The pancreas is usually enlarged and hypoechoic and may be seen in conjunction with hyperechogenicity of the peri-pancreatic fat which occurs due to saponification. Peritoneal fluid may accumulate around the pancreas due to localised peritonitis. There may be evidence of thickening of the wall of the stomach and/or duodenum and secondary ileus due to extension of inflammation. Enlargement of the lymph nodes (pancreaticoduodenal, hepatic, jejunal and splenic) draining the pancreas due to reactive change may be evident. The distal portion of the common bile duct is surrounded by the pancreas and may become obstructed due to compression from an inflamed pancreas.



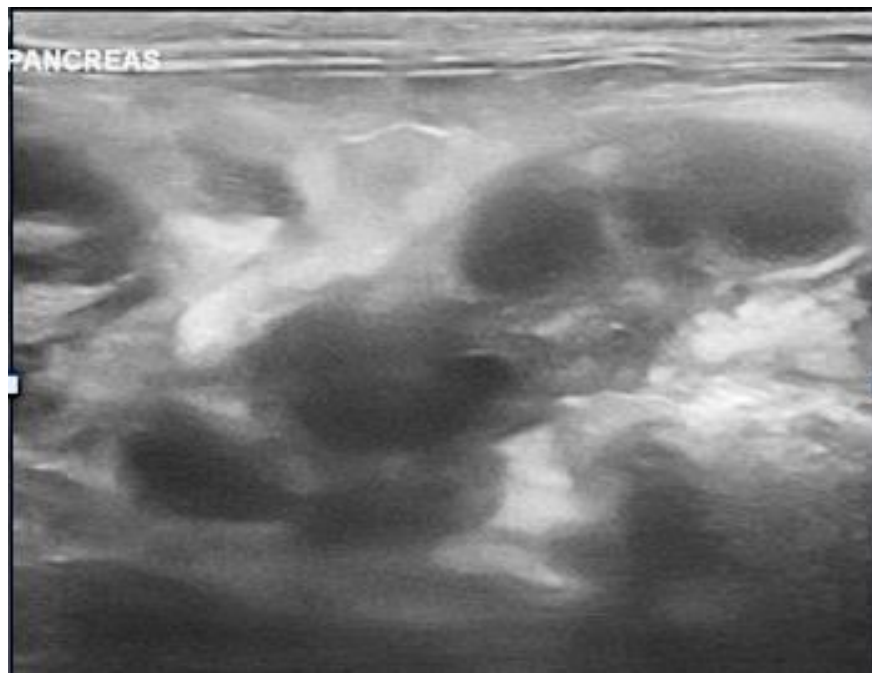
Severe pancreatitis affecting the right pancreatic limb in a dog.

Pancreatic neoplasia

Pancreatic neoplasia is rare. Adenocarcinoma is the most common malignant tumour of the exocrine pancreas in both dogs and cats and originates from the exocrine acinar or ductal epithelial cells. Airedale terriers are reported to have a breed predisposition to pancreatic adenocarcinomas which often present as a poorly or well-defined hypoechoic nodule or mass on ultrasound. They are aggressive tumours and metastasize readily to draining lymph nodes, the liver and peritoneum (known as carcinomatosis). Metastases are often present at the time of diagnosis.

Of the endocrine pancreatic tumours, insulinomas are the most common and arise from the beta cells. They typically form small hypoechoic nodules, often $\leq 2.5\text{mm}$ in diameter and are more common in large breeds of dog. These two factors combined, make locating an insulinoma potentially challenging on ultrasound, which has a low sensitivity for their detection. Dual phase computed tomography (CT) angiography has a much higher sensitivity for the detection of insulinomas in the dog. Iodinated contrast is injected intravenously and special bolus-tracking software is used to co-ordinate timed CT-scans of the pancreatic region resulting in arterial and venous phases. Insulinomas appear hyperattenuating (bright) compared with the surrounding pancreatic tissue due to rapid uptake of contrast during the arterial phase and show rapid wash-out of contrast on later phases. This enhancement pattern allows many insulinomas to be identified that may not have been recognised with ultrasound alone. Since insulinoma metastases also show the same enhancement pattern, spread to local lymph nodes (particularly the pancreaticoduodenal and hepatic) and to the liver, can also be seen.

It should be noted that the ultrasound-appearance of pancreatic neoplasia is not specific and cannot be definitively differentiated from pancreatitis and/or nodular hyperplasia. Therefore, findings should always be interpreted in line with the clinical history and any relevant blood work and if in doubt, fine needle aspiration can be undertaken.



Pancreatic lymphoma in a cat

Pancreatic cysts

Congenital pancreatic cysts are present from birth, have a true epithelial lining and have been associated with polycystic kidney disease in cats. They usually have a thin echogenic wall, anechoic contents and distal acoustic enhancement and are usually considered to be incidental.

Pseudocysts usually form as a result of pancreatitis. They contain pancreatic secretions originating from a duct that has ruptured into a region of necrosis. They may be thick or thin-walled and often resolve spontaneously. Rarely, they can become large enough to obstruct the common bile duct.

Pancreatic abscesses

Pancreatic abscesses are also often a sequel to pancreatitis and can arise due to infection of a pseudocyst. They usually have a thick, irregular echogenic wall and variably echogenic contents, which may show evidence of sedimentation and distal acoustic enhancement and can appear very similar to a pseudocyst on ultrasound. Hyperechoic foci associated with either reverberation artefact or acoustic shadowing may be seen and represent gas secondary to gas-forming bacteria or mineralisation respectively. Abscesses may be drained under ultrasound-guidance and some may need to be excised surgically.

Sampling the pancreas

Fine needle aspiration of the pancreas can be performed safely and is usually indicated either when there is a suspicion of neoplasia or to determine the nature of a cavitated lesion. A study assessing the serum pancreatic enzyme levels in 27 healthy dogs before and after fine needle aspiration reported no elevations in enzyme levels following the procedure. Tru-cut biopsy is also possible however this should be reserved for very large masses and fine needle aspiration would normally be performed initially.

References

1. Etu SM, Pennick DG, Labato MA, et al. Ultrasonography of the normal feline pancreas and associated anatomic landmarks: a prospective study of 20 cats. *Vet Radiol Ultrasound* 2001;**42**:330-6.
2. Laron MM, Panciera DL, Ward DI et al. Age-related changes in the ultrasound appearance of the normal feline pancreas. *Vet Radiol Ultrasound* 2005;**46**:238-42.
3. Hecht S, Pennick DG, Mahoney OM, et al. Relationship of pancreatic duct dilation to age and clinical findings in cats. *Vet Radiol Ultrasound* 2006;**47**:287-94.
4. Hecht S, Henry G. Sonographic evaluation of the normal and abnormal pancreas. *Clin Tech Small Anim Pract* 2007;**22**:115-21.
5. Saunders HM. Ultrasonography of the pancreas. *Probl Vet Med* 1991;**3**:583-603.
6. Saunders HM, Pugh CR, Rhodes WH. Expanding applications of abdominal ultrasonography. *J Am Anim Hosp Assoc* 1992;**28**:369-74.
7. Lamb CR, Simpson KW. Ultrasonographic findings in cholecystokinin-induced pancreatitis in dogs. *Vet Radiol Ultrasound* 1995;**36**:139-45.
8. Priester WA. Data from eleven United States and Canadian colleges of veterinary medicine on pancreatic carcinoma in domestic animals. *Cancer Res* 1974;**34**:1372-5.
9. Caywood DD, Klausner JS, O'Leary TP, et al. Pancreatic insulin-secreting neoplasms: clinical, diagnostic and prognostic features in 73 dogs. *J Am Anim Hosp Assoc* 1988;**24**:577-84.
10. Mai W, Cáceres AV. Dual-phase computed tomographic angiography in three dogs with pancreatic insulinoma. *Vet Radiol Ultrasound* 2008;**49**(2):141-8.
11. Cordner AP, Armstrong PJ, Newman SJ, et al. Effect of pancreatic tissue sampling on serum pancreatic enzyme levels in clinically healthy dogs. *J Vet Diagn Invest* 2010;**22**(5):702-7.

The Prostate Gland

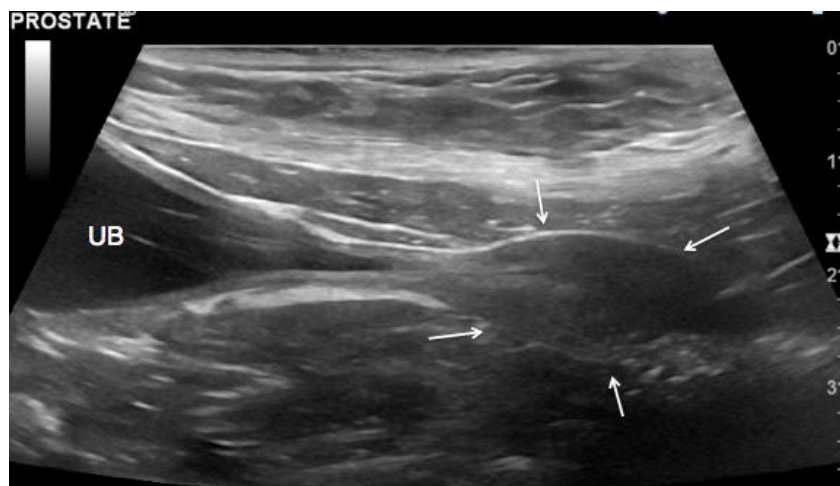
Location

I prefer to examine the prostate gland with the dog in right lateral recumbency and the left leg raised by an assistant. In many dogs the hair is relatively sparse in the caudoventral abdomen and in such cases, clipping may not be necessary. Always try to use the highest frequency possible that still provides the depth of penetration necessary. In many dogs however, the prostate can be tucked away quite caudally and may be partly intra-pelvic making it necessary to angle the probe caudally. This is much more easily done with a microconvex probe than a linear probe and hence it may be necessary at times to sacrifice some resolution.

The prostate gland is a bi-lobed organ that surrounds the proximal urethra and can be found by identifying the neck of the bladder and sliding the probe caudally whilst following the urethra. If you are still unable to see the prostate, it may be because it is entirely intra-pelvic. In these cases, it is often possible to push the prostate sufficiently cranially per rectum so that it can be scanned.

Normal appearance

The size of the prostate varies depending on the age and neutering status of the dog. In dogs neutered at an early age, the prostate remains small and elliptical throughout life. The prostate of neutered dogs is usually uniformly hypoechoic and the urethra, represented by an anechoic tube, may be visible running centrally through the gland. In entire males, the prostate gradually increases in size and becomes more rounded and hyperechoic. There appears to be little variation in the size of the prostate between breeds of dog with the exception of the Scottish Terrier, which naturally has a larger prostate than that of other breeds.



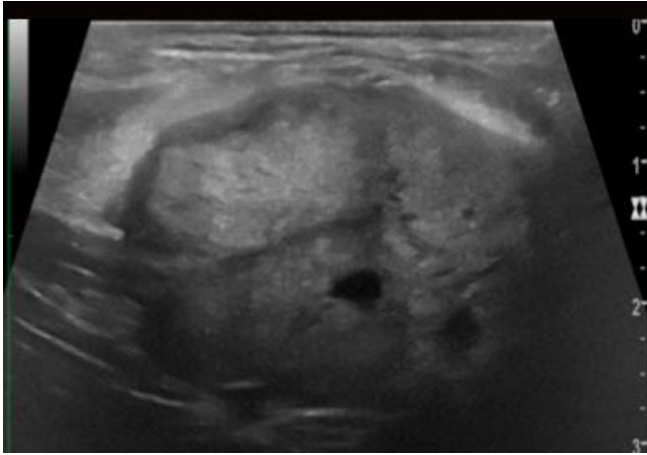
Normal prostate in an 18 year old neutered dog

Diseases of the canine prostate gland

Benign prostatic hyperplasia (BPH)

Enlargement of the prostate in the majority of dogs more than 5 years of age, commonly occurs due to benign prostatic hyperplasia and is the result of androgenic stimulation or an altered androgen:estrogen ratio. It is the most common prostatic abnormality to affect the canine prostate and may affect some individuals as early as 2.5 years of age.

Prostatomegaly is usually non-painful and symmetrical and whilst some animals show no clinical signs, prostatic enlargement can become marked and result in tenesmus, and haematuria. The prostatic parenchyma frequently develops a heterogenous echotexture with an overall increase in echogenicity. Multiple small cysts are often seen throughout the parenchyma. Mineralisation, evidence of prostatic capsule disruption and regional lymph node enlargement are not features of BPH.



Benign prostatic hyperplasia

Bacterial prostatitis

This is a condition that almost exclusively affects entire dogs and is usually due to bacteria ascending the urethra although it can also be due to bacterial descent from the kidney or haematogenous infection. The prostate is usually painful and the dog may be pyrexemic. On ultrasound, there is mild to moderate prostatomegaly and increased heterogeneity of the parenchyma. In chronic cases of prostatitis, mild mineralisation is possible although this is uncommon. Aside from mineralisation, hyperechoic foci may be apparent due to the presence of parenchymal gas following infection and is usually associated with reverberation artefact. Abscesses may form within the prostate and extension of inflammation into the peri-prostatic tissues can result in hyperechogenicity of fat and localised peritoneal fluid. If the medial iliac and/or hypogastric lymph nodes are affected, changes are usually mild.

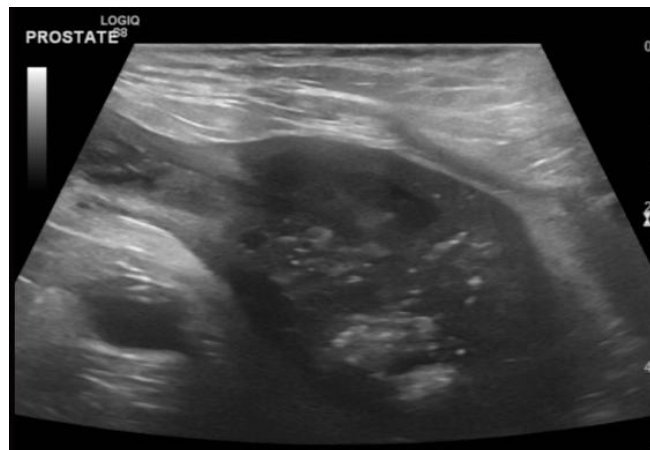Paraprostatic cysts

Paraprostatic cysts are cysts located adjacent to the urinary bladder that arise from the prostate and are sometimes difficult to differentiate from the urinary bladder. Egg-shell like mineralisation of the cyst wall has been described and when present, can cause an acoustic shadow on ultrasound and may be visible on radiographs. Due to being similar in appearance to the urinary bladder, the two are easily confused. Inserting a urethral catheter or carefully following each structure caudally to assess its position with respect to the prostate can help the operator to differentiate between the two.

Prostatic neoplasia

Neoplasia of the prostate typically affects older dogs. Affected individuals may be neutered or entire however several studies have shown a strong link between castration and increased risk of prostatic neoplasia. A wide range of tumours affect the prostate gland however the most common primary prostatic neoplasm is adenocarcinoma. Prostatic neoplasia can spread to the urethra and bladder trigone region where it can cause obstruction of the bladder and one or both ureteral openings leading to hydronephrosis and hydroureter. The opposite is also true whereby tumours originating in the bladder or proximal urethra can also extend into the prostate.

Prostatic neoplasia usually causes enlargement of the gland however this may not be as marked as that resulting from BPH. Neoplasia may be more difficult to detect in entire dogs due to the presence of other conditions such as BPH which can at least initially, mask the presence of neoplastic infiltrates. Enlargement may be asymmetric and break through the prostatic capsule. Mineralisation is a relatively common feature. Extension of changes to the urethra and bladder trigone is also highly suggestive of neoplasia.



Confirmed prostatic carcinoma

Since metastases are common the sublumbar lymph nodes should be assessed. Often, only the medial iliac lymph nodes are visible however it may be possible to see the hypogastric nodes in some dogs. Marked enlargement, rounding and reduced echogenicity of the nodes suggests the possibility of metastatic disease. Where possible, fine needle aspirates should be performed to confirm the diagnosis, taking care to avoid the adjacent aorta and caudal vena cava. This should only be attempted if the operator is confident in performing fine needle aspiration. Prostatic neoplasia also commonly metastasizes to the lumbar vertebral bodies and lungs.

References

1. Bell FW, Klausner JS, Hayden DW, et al. Clinical and pathologic features of prostatic adenocarcinoma in sexually intact and castrated dogs: 31 cases (1970-1987). *J Am Vet Med Assoc* 1991;**199**:1623-30.
2. Teske E, Naan EC, van Dijk EM, et al. Canine prostate carcinoma: epidemiological evidence of an increased risk in castrated dogs. *Mol Cell Endocrinol* 2002;**197**(1-2):251-5.
3. Bryan JN, Keeler MR, Henry CJ, et al. A population study of neutering status as a risk factor for canine prostate cancer. *Prostate* 2007;**67**(11):1174-81.
4. Bradbury CA, Westropp JL, Pollard RE. Relationship between prostatomegaly, prostatic mineralisation, and cytological diagnosis. *Vet Radiol Ultrasound* 2009;**50**(2):167-71.
5. Lee-Parritz DE, Lamb CR. Prostatic adenocarcinoma with osseous metastasis in dog. *J Am Vet Med Assoc* 1988;**192**:1569-72.
6. Powe JR, Canfield PJ, Martin PA. Evaluation of the cytological diagnosis of canine prostatic disorders. *Vet Clin Pathol* 2004;**33**(3):150-4.
7. Nyland TG, Wallack ST, Wisner ER. Needle-tract implantation following US-guided fine-needle aspiration biopsy of transitional cell carcinoma of the bladder, urethra and prostate. *Vet Radiol Ultrasound* 2002;**43**(1):50-3.
8. Ladds PW. The male genital system. In: Jubb KVF, Kennedy PC, Palmer N, editors. *Pathology of Domestic Animals*. 4th ed. Orlando, Fla: Academic Press; 1993. P. 471-529.
9. Atiola MAO, Pennock PW. Cystic uterus masculinus in the dog. *Vet Radiol* 1986;**27**:8-14.
10. Stowater JL, Lamb CR. Ultrasonographic features of paraprostatic cysts in dogs. *Vet Radiol* 1989;**30**:232-9.