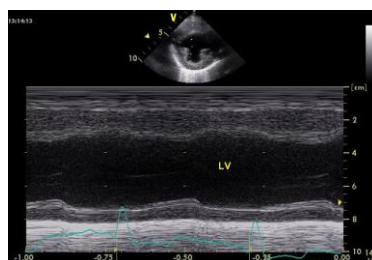




Cardiac Ultrasound Mini Series

Session One: Getting Good images and Doing Simple Things Well First

Domingo Casamian Sorrosal DVM CertSAM
DipECVIM-CA DVC MRCVS
RCVS Specialist in Veterinary Cardiology and
European Specialist in Small Animal Internal Medicine



Echocardiography in small animals Part 1

*Domingo Casamian-Sorrosal DVM Cert SAM DVC DECVIM-CA MRCVS
RCVS Recognised Specialist in Veterinary Cardiology
Cardiology Service
Dick White Referrals*



Abbreviations

ATE: Aortic thromboembolism
CHF: Congestive heart failure
DCM: Dilated Cardiomyopathy
HCM: Hypertrophic cardiomyopathy
HOCM: Hypertrophic obstructive cardiomyopathy
IVS: Interventricular septum
IVSW: Interventricular septal wall
LA: Left atrial enlargement
LV: Left ventricle
LVFW: Left ventricular free wall
RV: Right ventricle
SAM: Systolic anterior movement of the mitral valve
VSD: Ventricular septal defect

Introduction

Cardiac disease is common in dog and cats and echocardiography is of paramount importance for its diagnosis. Whilst full echocardiographic examination is usually performed by cardiologists, knowledge of the basics of echocardiography and thoracic ultrasonography will help with decision making in many clinical situations such as when cats and dogs present with respiratory distress. In this instance a thoracic/cardiac scan can prove very useful.

Getting ready for echocardiography

Echocardiography is usually carried out in lateral recumbency. The basic initial view is the right parasternal; and thus the patient needs to be positioned in right lateral recumbency. We will also discussed in session 2 some left parasternal views for those willing to go beyond basic echocardiography.

A special customised table with “a hole” to allow probe placement is needed. Although lateral recumbency is desired because it improves the contact of the heart with the chest wall, standing basic echocardiography and thoracic ultrasonography are often very useful and carry less risk of causing significant cardiorespiratory compromise in unstable patients.

The probes used for echocardiography in cats need to have high frequency and a small “footprint”. Small sector phased array and occasionally microconvex probes are used. The probe frequency varies but 7.5-10MHz probes are usually the best. For dogs standard sector phased array probes with frequencies between 2.5 and 7.5 MHz are used. A rule of thumb is that the bigger the dog the lower frequency probe is required and viceversa. It is very important to clip the patient well, in particular for high frequency probes and hairy or obese patients. Before clipping, feel the apex beat which is the place where your echocardiographic examination is started. It is common to clip too high and too caudal if the apex is not first palpated. Spirit and echocardiographic gel should be applied to minimise artefact and facilitate visualisation.

The probe should be held with your thumb placed over the probe marker. You should be comfortable when carrying out echocardiography and one hand should be holding the probe while the other is adjusting/modifying machine settings.

Specific “cardiac knobology”

Echocardiography: Temporal resolution is the ability to resolve structures with respect to time (keeping up with the actual events) and it is very important in echocardiography where the heart is a fast moving structure as oppose to abdominal viscera for example. This is usually dependent upon the frame rate and the pulse repetition frequency. Temporal resolution will be improved by reducing the sector width and image depth.

As is the case in abdominal ultrasonography; lateral and axial resolution are also important and can be improved further by using high frequency probes, using the focus marker and with the use of harmonics. The gain should also be adjusted appropriately as discussed for abdominal ultrasonography.

Artifacts in echocardiography

The most common artifacts in echocardiography are breathing and movement artifact, the side lobe artifact and the reverberation/mirror artifact. We have to be aware of these artifacts in order not to confuse them with cardiac abnormalities.

Movement artifact can be diminished in by good animal handling or sedation. Side lobe artifact: All transducers generate sound beams lateral to the central beam. Reflections from structures along the side lobes reach the transducer but the machine may think that they have been generated by the central beam and if there is no structure reflecting sound waves from the central beam the machine may give erroneous information. This side lobe artifact commonly occurs for example within the left atrium on a right parasternal long axis view.

Mirror artifact: Reverberation occurs when strong reflectors are encountered within the thorax. These structures send such strong echoes back that the sound beams are reflected back and travel to the heart and back to the transducer for a second time. As the echoes take twice as long the machine “thinks” that the structures are twice as deep and a mirror image is created. A typical mirror artifact in echocardiography is caused by a very reflective pericardium, causing a cardiac mirror image just below the pericardium.

Sedation during echocardiography

The decision to sedate a patient will be taken on a case-to-case basis. It will depend upon the animal stress during echocardiography and the underlying disease and health state of the patient. Non-sedated echocardiography is always preferred and this is usually possible in a friendly environment with good handling skills. The author uses butorphanol or butorphanol and midazolam given IV in dogs. For cats butorphanol IV or if the cat is extremely fractious a combination of alphaxolane, midazolam and butorphanol can be given IM.

Basic echocardiographic views

Right parasternal long axis view- 4-chambers

Position:

1. Patient in left lateral recumbency
2. Probe on right lateral chest wall
3. Hold the probe with your finger on the reference mark
4. Place the probe where the apex beat is (feel the apex beat)
5. Point towards the scapula on the other side
6. Make adjustments to have the most horizontal picture possible

This view can be used for:

1. Subjective cardiac chambers size:
RV 1/3 of LV; IVS similar to LVFW; RVFW ½ IVSW/LVFW
2. Subjective assessment of the heart, in particular of left/right ventricular enlargement, wall thickening and systolic function
3. Diagnosing pericardial effusion
4. Assessment of LA size (<16mm in systole) and smoke (slow moving blood)
5. Mitral and tricuspid valve appearance

Right parasternal long axis view- left ventricular outflow tract

Position:

1. From your 4-chamber position
2. Rotate 10 degrees anticlockwise
3. Optimise the image to (if possible) observe the LV outflow tract and the ascending aorta

This view can be used for:

1. Assessment of the aortic valve (e.g. endocarditis)
2. Assessment of SAM in HCM cats
3. Assessment of a VSD
4. Assessment of aortic and subaortic stenosis

Right parasternal short axis (transverse) view- left ventricle

Position:

1. From your 4-chamber position
2. From the long axis view rotate 90 degrees
3. For rotation keep the wrist fixed and adjust the image by rotating the probe rather than the wrist. This will allow better probe manoeuvring.
4. Slide and/or angle until a view of the papillary muscles (just below the mitral valve) appears
5. For M-mode optimise the image for the line to be crossing the LV perpendicularly (difficult in cats)
6. Sliding or angling slightly dorsally a transverse view of the mitral valve can also be obtained.

This view can be used for:

1. Measuring wall thickening (to detect hypertrophy) and LV dimensions in systole and diastole. Two-dimensional echo is preferred in cats and M-mode is preferred in dogs (all measurements need to be carried out just below the mitral valve).
2. Diagnosis of pericardial effusion
3. Calculation of fractional shortening (systolic function parameter)
4. M-mode at the level of the mitral valve can be carried out to calculate the EPSS (E point of septal separation) which can also be used as a systolic parameter (normal below 0.7 cm).

Right parasternal short axis (transverse) view- heart base

1. From the previous short axis view at the level of the left ventricle- move (preferred) or angle your probe dorsally
2. There is often a need to move cranially and adjust the view by rotation
3. The three cusps of the aorta (Mercedes Benz sign) and the LA with a well-defined auricle should be seen

This view can be used for:

1. Assessment of the left atrium size (aorta/left atrium ratio; normal <1.5)
2. Visualisation of smoke or clots

Echocardiographic findings in disease

Normal values for left ventricular

Reference intervals have been reported for dogs and cats. It is a very common mistake when starting to carry out echocardiography to rely solely on numbers for diagnosis. The numbers need to be put into the context of the subjective cardiac appearance and the whole case context.

For dogs, breed values or allometric scaled values should be used. I include below a guide of approximate intervals by weight adapted by allometric scaling.

Although there is a variation with weight values in cats, the values tend to be more homogeneous and general reference intervals are commonly used.

Table 4. Normal M-mode average values and prediction intervals for dogs of varying weights.^a

Body wt. (kg)	LVID _d	LVID _s	LVW _d	LVW _s	IVST _d	IVST _s	Ao	LA
3	2.1	1.3	0.5	0.8	0.5	0.8	1.1	1.1
	1.8–2.6	1.0–1.8	0.4–0.8	0.6–1.1	0.4–0.8	0.6–1.0	0.9–1.4	0.9–1.4
4	2.3	1.5	0.6	0.9	0.6	0.8	1.3	1.2
	1.9–2.8	1.1–1.9	0.4–0.8	0.7–1.2	0.4–0.8	0.6–1.1	1.0–1.5	1.0–1.6
6	2.6	1.7	0.6	1.0	0.6	0.9	1.4	1.4
	2.2–3.1	1.2–2.2	0.4–0.9	0.7–1.3	0.4–0.9	0.7–1.2	1.2–1.8	1.1–1.8
9	2.9	1.9	0.7	1.0	0.7	1.0	1.7	1.6
	2.4–3.4	1.4–2.5	0.5–1.0	0.8–1.4	0.5–1.0	0.7–1.3	1.3–2.0	1.3–2.1
11	3.1	2.0	0.7	1.1	0.7	1.0	1.8	1.7
	2.6–3.7	1.5–2.7	0.5–1.0	0.8–1.5	0.5–1.1	0.8–1.4	1.4–2.2	1.3–2.2
15	3.4	2.2	0.8	1.2	0.8	1.1	2.0	1.9
	2.8–4.1	1.7–3.0	0.5–1.1	0.9–1.6	0.6–1.1	0.8–1.5	1.6–2.4	1.6–2.5
20	3.7	2.4	0.8	1.2	0.8	1.2	2.2	2.1
	3.1–4.5	1.8–3.2	0.6–1.2	0.9–1.7	0.6–1.2	0.9–1.6	1.7–2.7	1.7–2.7
25	3.9	2.6	0.9	1.3	0.9	1.3	2.3	2.3
	3.3–4.8	2.0–3.5	0.6–1.3	1.0–1.8	0.6–1.3	0.9–1.7	1.9–2.9	1.8–2.9
30	4.2	2.8	0.9	1.4	0.9	1.3	2.5	2.5
	3.5–5.0	2.1–3.7	0.6–1.3	1.0–1.9	0.7–1.3	1.0–1.8	2.0–3.1	1.9–3.1
35	4.4	2.9	1.0	1.4	1.0	1.4	2.6	2.6
	3.6–5.3	2.2–3.9	0.7–1.4	1.1–1.9	0.7–1.4	1.0–1.9	2.1–3.2	2.0–3.3
40	4.5	3.0	1.0	1.5	1.0	1.4	2.7	2.7
	3.8–5.5	2.3–4.0	0.7–1.4	1.1–2.0	0.7–1.4	1.0–1.9	2.2–3.4	2.1–3.5
50	4.8	3.3	1.0	1.5	1.1	1.5	3.0	2.9
	4.0–5.8	2.4–4.3	0.7–1.5	1.1–2.1	0.7–1.5	1.1–2.0	2.4–3.6	2.3–3.7
60	5.1	3.5	1.1	1.6	1.1	1.5	3.2	3.1
	4.2–6.2	2.6–4.6	0.7–1.6	1.2–2.2	0.8–1.6	1.1–2.1	2.5–3.9	2.4–4.0
70	5.3	3.6	1.1	1.6	1.1	1.6	3.3	3.3
	4.4–6.5	2.7–4.8	0.8–1.6	1.2–2.2	0.8–1.6	1.2–2.2	2.7–4.1	2.6–4.2

LVID_d, left ventricular end diastolic diameter; LVID_s, left ventricular end systolic diameter; LVW_d, left ventricular free wall thickness in diastole; LVW_s, left ventricular free wall thickness in systole; IVST_d, interventricular septal thickness in diastole; IVST_s, interventricular septal thickness in systole; Ao, aortic root diameter; LA, left atrial diameter.

^a Mean and 95% prediction interval (cm).

Cornell et al 2004. JVIM 18; 311-321

	<u>Normal</u>	<u>DCM</u>	<u>HCM</u>	<u>RCM</u>
<u>LVDs</u> <u>(mm)</u>	6.7-9.7 (<12)	>11-12	Normal or decreased	Normal or decreased
<u>LVDd</u> <u>(mm)</u>	14-17 (<18)	>18	Normal or decreased	Normal or decreased
<u>LVPWd/</u> <u>IVSWd</u> <u>(mm)</u>	3.0-4.2 (<6)	Normal or decreased	> 6 mm	< 6 mm
<u>FS (%)</u>	36-52% (<55)	<30%	Normal or Increased	Normal or decreased

Major pitfalls

Technique

Errors will lead to misdiagnosis. Echocardiography in cats is often more difficult than in dogs due to the fact that they are often less easily restrained, structures are smaller and the heart beats faster. These are some of the most common technique errors:

1. Measuring the left ventricle and atrium at the wrong cycle timing under/overestimating wall and/or lumen size.
2. Measuring the left ventricle on a short axis view at the wrong level within the left ventricle overestimating the degree of hypertrophy or left ventricular enlargement (measuring too low in the ventricle).
3. Including in your left ventricular measurement (particularly on M-mode) the papillary muscle which leads to overestimation of the degree of hypertrophy.
4. Obtaining suboptimal views (e.g. oblique views), which will lead to under/overestimating LV wall thickening, or the luminal atrial or ventricular size.
5. Confusing in cats a LV fibrous band with the endothelium overestimating the degree of LV hypertrophy.

Intrinsic to basic echocardiography

Even if you obtain good images and measurement there are limitations that should be taken into account when attempting to diagnose cardiac disease in cats and dogs. These are some of them:

1. Left ventricular hypertrophy does not always mean HCM in cats (this may be due to dehydration/hypervolemia, hyperthyroidism, hypertension, AS)
 2. Left ventricular systolic dysfunction does not always means DCM in dogs (this may be due to cardiomyopathy of overload, tachycardiomyopathy, systemic disease, myocarditis, normal variation or an athletic heart)
- Secondary cardiomyopathies (hyperthyroidism and systemic arterial hypertension) are very common in cats

2. Diagnosing HCM or DCM is not only based on left ventricular thickening or systolic dysfunction respectively, it is a sum of echocardiographic findings put into the right case context
3. Cardiac disease does not mean CHF

Thoracic ultrasonography

Thoracic ultrasonography can be an extremely useful tool in general practice. It is usually carried out in standing position although lateral recumbency is also valid. Small footprint micro-convex and sector probes are desired although linear probes are sometimes used for structures very near the chest wall. The lungs could be explored from a thoracic inlet window, from a subcostal window or from an intercostal window. The latter is usually the most useful and each hemi-thorax can be divided in 4 quadrants for a comprehensive examination. Lung ultrasonography relies on artefacts and excessive filters (e.g. when using harmonics) may actually give a less desirable image.

Ultrasonography of the normal lung:

1. Visualisation of the pleural line
2. Distinct layers of parietal and visceral pleura are seen
3. Absence of soft tissue structures underneath the pleural line. The lung-soft tissue interface causes reflection of the sound waves creating a “dirty shadow” and multiple parallel artefact-type lines called A-lines.
4. At both sides of this typical lung image the hypoechoic shadowing of the ribs can be seen at both sides of the normal lung surface (creating the so called bat sign).

Ultrasonography of pleural effusion:

1. There is a hypoechoic layer between the parietal pleura and the lung or mediastinum.
2. Free floating structures and/or lung movement is often observed.
3. This “fluid-layer” can be anechoic (e.g. transudates) or mixed echoic (exudate, haemorrhage, neoplastic effusions).
4. Pneumothorax is difficult to diagnose by ultrasound.

Ultrasonography of the abnormal lung:

1. Possible when alveolar air is replaced by fluid, tissue or if the lung lobes have collapsed
2. Consolidated lung lobes will have a tissue-like appearance, often called hepatisation. Residual air within the lung may be seen as hyperechoic speckles particularly during inspiration. Fluid-filled bronchi may be seen as hypoechoic tubular structures with hyperechoic walls (fluid-bronchograms).
3. Partial consolidation (non-transeptal consolidation) is often seen with interruption of the smooth hyperechoic pulmonary surface by vertical streaks (shred sign).
4. Atelectasis is often found in pleural effusions and visualised as small triangular consolidated structures with variable degree of air (reverberation artefact) within the airways.
5. Pulmonary masses also appear as soft-tissue structures but they tend to be irregular and round, with distortion of the normal lung architecture.

Ultrasonography of interstitial disease (e.g. pulmonary oedema):

1. Comet tail artefacts (B-lines), which are hyperechoic laser-like artefact arising from the pleural surface and erasing A lines may be seen
2. Three or more are called lung “rockets”
3. There is a great degree of variation particularly for a beginner ultrasonographer and this should always be interpreted together with other thoracic imaging modalities.

Ultrasonography of mediastinal masses:

1. The cranial mediastinum is easily evaluated through a thoracic inlet window or a cranial intercostal window.
2. Soft tissue round or irregular structures in the cranial mediastinum.
3. Mediastinal cysts appear as hypoechoic structures with a thin wall.
4. If large, these masses can be easily aspirated.