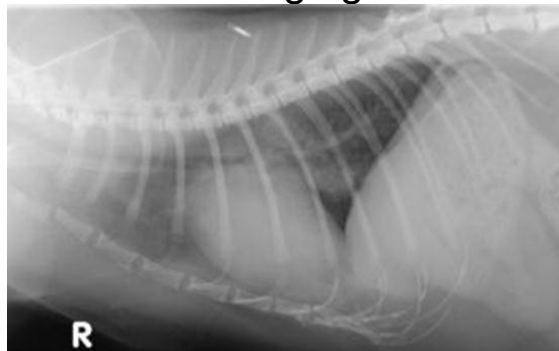


Thoracic Radiology 'Mini Series'

Session 2: Heart and Thoracic Vessels

Esther Barrett

MA VetMB DVDI DipECVDI MRCVS
RCVS & European Specialist in Veterinary Diagnostic
Imaging



The Heart and Thoracic Vessels

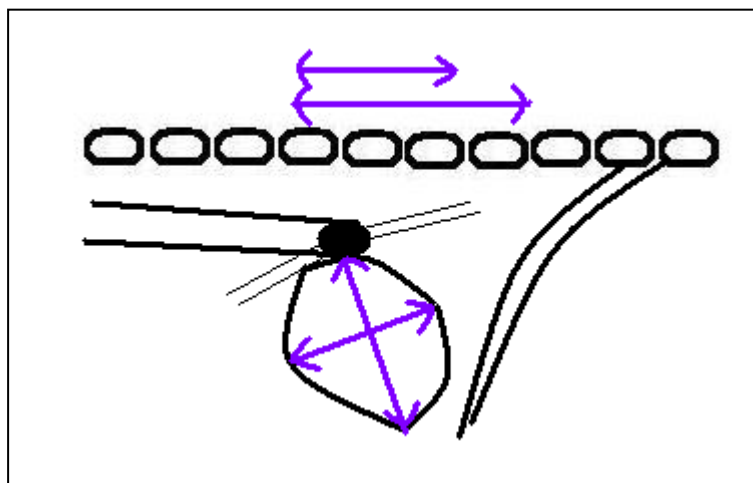
The Heart

Normal Anatomy

- ♦ The cardiac silhouette is the largest single soft tissue opacity in the thorax comprises the heart itself, together with a small amount of pericardial fluid between the 2 layers (fibrous and serous) of the pericardium
- ♦ Radiography allows an assessment of overall cardiac size and shape, but an evaluation of the internal structure and function of the heart requires echocardiographic (or angiocardiographic) examination

Normal size – Dogs

- ♦ Marked breed variation
- ♦ Typically between 2.5 & 3.5 intercostal spaces in width on the lateral view
- ♦ Approximately 2/3 of the height of the thorax on the lateral view
- ♦ Typically 60-65% (DV view) or up to 2/3 (VD view) of the width of the thorax
- ♦ **Vertebral heart score (Buchanan 1995)**
 - Normal canine VHS 10+/-1 (puppies 8.5-10.5)
 - Measure the long axis (ventral aspect of carina to apex) and short axis (perpendicular to long axis at widest point) on the lateral view
 - Convert these into 'vertebral lengths' (to nearest 0.1), starting at the cranial end of T4 for both measurements & sum them to give the VHS



Normal size – Cats

- ◆ Little breed variation
- ◆ Width on lateral view should be \approx distance from cranial rib 5 to caudal rib 7
- ◆ Width on DV view should be $<$ than 4 vertebral lengths from cranial T4 (measured on the lateral view)
- ◆ Approximately 2/3 of the height of the thorax on the lateral view
- ◆ VHS 7.5 \pm 0.5

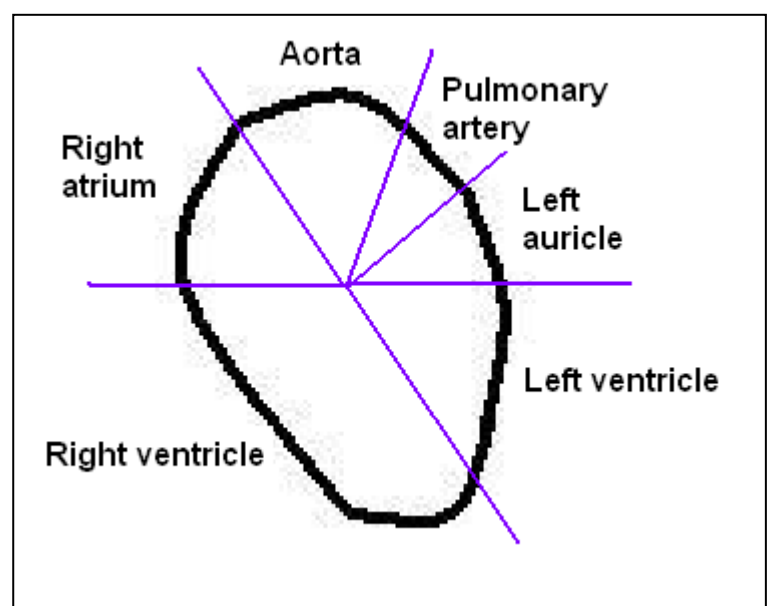
Normal shape and position

Lateral view

- ◆ Lop sided egg shape with base dorsal and apex ventral
- ◆ Right atrium (cranio-dorsal) and right ventricle (cranio-ventral) comprise cranial cardiac border
- ◆ Left atrium (caudo-dorsal) and left ventricle (caudo-ventral) comprise caudal cardiac border
 - In cats, the left atrium is more cranially located

DV view

- ◆ Dogs: egg shaped with apex to left of midline
- ◆ Cats: more oval with apex closer to midline
- ◆ 'clock face' analogy to describe location of cardiac chambers
 - Aorta 11-1 o'clock
 - Pulmonary artery 1-2 o'clock
 - Left auricle 2-3 o'clock (1-2 o'clock in the cat with the pulmonary artery further cranially or not seen)
 - Left ventricle 3-5 o'clock
 - Right ventricle 5-9 o'clock
 - Right atrium 9-11 o'clock



The Great Vessels

Normal Anatomy

Aorta

- Easily seen on the lateral view,
 - The ascending aorta is short and arises from the cranial aspect of the heart. It is not clearly seen.
 - The aortic arch is also short & curves cranio-dorsally from cranial aspect of the heart base before turning caudally
 - To run ventral to the thoracic spine towards the abdomen as the much longer descending aorta
- Should be similar in diameter to the caudal vena cava and to the height of the thoracic vertebral bodies
 - Size does not alter with hypovolaemia or volume overload
- Focal bulging of the aorta at the junction between the ascending aorta & aortic arch is often seen as an incidental finding in older cats
- The aorta should be visible on a well exposed DV view, emerging from the cardiac silhouette at 11-1 o'clock with the left border seen running caudally along /just to the left of midline

Caudal Vena Cava

- Seen on the lateral view leaving the right diaphragmatic crus (within the plica cava), crossing between the accessory & right caudal lung lobes to enter the right atrium, merging with the caudo-dorsal cardiac silhouette
- Usually (but not always) slopes caudo-dorsal to cranio-ventral
- May be parallel sided or widen towards the heart
- Should be visible on the DV view emerging from the diaphragm to the right of the midline
- Unlike the aorta, size can be affected by hypovolaemia or volume overload
- Temporary and incidental changes in size due to variation in the respiratory and cardiac cycle are also common

Cranial Vena Cava

- Merges with the soft tissue structures on the cranial mediastinum and not seen as a separate structure unless highlighted by a pneumomediastinum

The pulmonary vessels

Normal Anatomy

- ◆ The pulmonary vessels run in pairs (artery and vein) to each lung lobe
- ◆ Veins run **ventral and central** to their respective arteries
- ◆ Arteries are dorsal and lateral to the veins & follow the bronchial tree closely
- ◆ Vessel size; arteries & veins of the same pair should be similar in size
 - DV view (less well seen on VD): the diameter of the caudal lobar artery and vein should not exceed the width of the ninth rib where they cross
 - Lateral view: the diameter of the cranial lobar artery and vein should be
 - 0.75 ± 0.25 x the width of the proximal 1/3 of the 4th rib in the dog where they cross
 - cranial lobar artery should be 0.5-1.0 x the width of the proximal 1/3 of the 4th rib in the cat
 - The vessels should be well seen in the central and middle areas of the lung fields and taper towards the periphery

Cardiovascular Pathology and Radiographic Changes

With disease, the heart and vessels may change in size, shape, position and occasionally in margination and opacity. Some changes occur directly as a result of disease in the organ concerned, some may be due to disease in adjacent structures and some may be incidental findings. Disease may also exist without radiographic change. The increasing use of echocardiography has revealed that radiography alone can be misleading in the diagnosis of cardiac disease.

Changes in Size and Shape

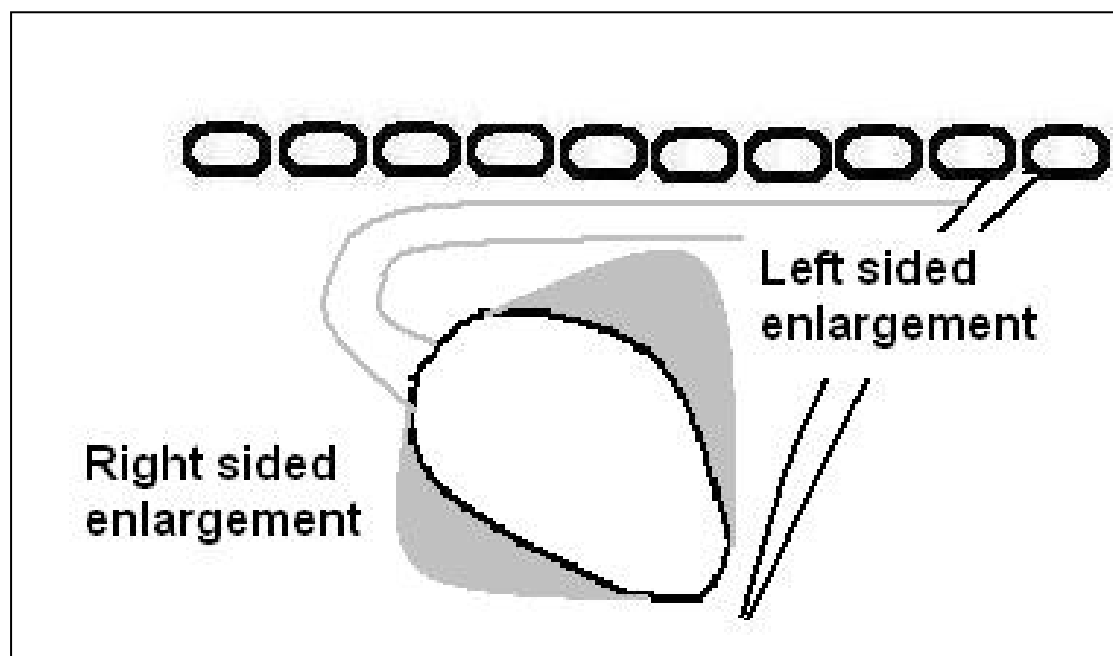
Microcardia

- Diagnosed when cardiac size is smaller than normal values
- Typically appears narrow on both DV/VD and lateral views
- May lose sternal contact as it becomes increasingly 'pointed' in shape
- May be accompanied by a reduction in the size of pulmonary vessels & CdVC
- Differential diagnoses include:
 - Hypovolaemia eg due to dehydration or shock

- Loss of muscle mass, eg due to emaciation, atrophic myopathy
- Addison's (chronic electrolyte abnormalities result in a smaller heart)
- Beware overdiagnosis of a small heart in:
 - Deep chested dogs with tall, upright hearts
 - Overinflated lungs, where the heart appears small relative to the hyperinflated lung fields

Cardiac Enlargement

- Diagnosed when the radiographic cardiac size exceeds normal parameters
 - Beware of breed variation
 - Can be mimicked by poor radiographic positioning
 - Detection of mild cardiomegaly is usually difficult and inaccurate
- Cardiomegaly may be generalised or maybe predominantly left or right sided
 - Radiography is limited in the evaluation of individual chamber enlargement
- Cardiac enlargement is not the same as cardiac failure
- Although echocardiography is central to the work up of cardiac disease, radiography is essential in the evaluation of the pulmonary changes which may occur secondary to heart disease



Right sided cardiomegaly

- Commonly overdiagnosed on thoracic radiographs
- Right atrial enlargement is very unusual as a solo finding & difficult to identify
- Right ventricular enlargement
 - Rounding of the cranial cardiac border and increased sternal contact on the lateral view (NB 'normal' shape for some barrel chested dogs)
 - Normally 2/3 of the cardiac silhouette should lie cranial to a line from the carina to cardiac apex. 4/5 + suggests right sided enlargement
- Tilting of the cardiac apex caudodorsally away from the sternum on lateral view (sensitive sign, but not always present)
- Rounding of the right cardiac silhouette on DV view to give 'Reverse D' shape
 - Often more reliable than changes seen on lateral view
- True right ventricular enlargement is often accompanied by left sided changes & right atrial enlargement
- Some more common differential diagnoses include:
 - Congenital: pulmonic stenosis, tricuspid valve dysplasia (more common in cat)
 - Acquired: cor pulmonale (right sided heart disease secondary to pulmonary hypertension)

Right sided heart failure

- Pleural effusion (may be due to a combination of right and left sided failure)
- Distension of caudal vena cava
- Hepato-splenomegaly
- Ascites
- Pericardial effusion (most frequently a cause of right sided failure, but occasionally a result)

Left sided cardiomegaly:

Left atrium

- Lateral view
 - Dorsal elevation +/- compression of the left caudal mainstem bronchi (look for splitting of the bronchi)
 - 'Tenting' of the left atrium
 - Seen as a triangular soft tissue opacity extending from the caudo-dorsal cardiac silhouette, resulting in increased height of the caudo-dorsal border
 - In cats, the more cranially positioned LA is harder to identify
- DV View
 - Enlargement of the left atrium is superimposed on the cardiac silhouette at 5 -7 o'clock and can push the caudal bronchi apart
 - 'Cowboy legs' sign (differential diagnosis = tracheobronchial lymph node enlargement)
 - The resulting increased soft tissue thickness may be seen as increased opacity
 - In the cat, an enlarged LA may be seen at left cranial cardiac margin (1-2 o'clock), & in severe cases may cause the apex to shift to the right

Left ventricle

- Lateral view
 - Straightening of the caudal cardiac silhouette
 - Elevation of the trachea and carina
- DV View
 - Enlarged left ventricle may elongate the cardiac silhouette
 - Cardiac apex may appear rounder and be displaced to the left

Some more common differential diagnoses for left sided cardiomegaly include:

- Congenital: persistent ductus arteriosus (PDA), ventricular septal defect (VSD), aortic stenosis (but cardiac silhouette often normal)
- Acquired: mitral endocardiosis, dilated cardiomyopathy

Left sided heart failure

- Vascular congestion
 - Pulmonary veins increase in diameter
- Cardiogenic pulmonary oedema
 - Appearance ranges from interstitial to severe alveolar pattern
 - Typically perihilar in the dog
 - Right caudal lobe also a predilection site, best seen on DV
 - More patchy and asymmetrical in the cat
- Pleural effusion in cats (mechanism poorly understood, but likely due to an anatomical variation in visceral pleural drainage)

Pericardial Effusion

- Globular cardiac enlargement on both lateral and DV views with no identifiable enlargement of individual cardiac chambers
- Typically sharply marginated cardiac borders as cardiac movement is 'hidden' within the pericardial fluid
- Accompanied by radiographic signs of right sided heart failure
- Lung fields may be underperfused due to cardiac tamponade
- Echocardiography demonstrates an anechoic effusion surrounding the heart and provides a quick, easy and accurate diagnosis of pericardial effusion
- Possible aetiologies (dogs)
 - Idiopathic 'benign' pericardial effusion
 - Secondary to neoplasia
 - Haemangiosarcoma
 - Heart base tumours
 - Mesothelioma
 - Less commonly
 - Secondary to right sided failure
 - Left atrial rupture
 - Septic pericarditis
- Possible aetiologies (cats)
 - Hypertrophic cardiomyopathy
 - FIP
- Echocardiographic examination needed to look for underlying causes
- Remember to screen for abdominal /thoracic metastases in case of neoplasia

Peritoneopericardial diaphragmatic hernia (PPDH)

- Congenital condition where abdominal organs are herniated into the pericardial sac
- Marked enlargement of the cardiac silhouette
- Heterogenous appearance of cardiac silhouette due to the presence of falciform/mesenteric fat and intestinal gas in addition to soft tissue structures
- May be cranial displacement of abdominal organs
- Typically no signs of congestive heart failure
- Often seen together with sternal abnormalities and abdominal wall defects (eg umbilical hernia)

Radiographic abnormalities of The Great Vessels

The Aorta

- Enlargement of the aortic arch or descending aorta
 - ◆ Best seen as a prominent bulge at 11-1 o'clock on the DV view, causing widening of the cranial mediastinum at this point
 - Beware normal prominence of the aorta on a VD view
 - ◆ May be seen as focal bulge on the cranial aspect of the heart on the lateral view
 - ◆ Differential diagnoses include:
 - 'Normal' finding in brachycephalic dogs and in older cats with a more horizontally positioned heart
 - Aortic stenosis with secondary post stenotic dilation
 - Large left-to-right shunting PDA

The Caudal Vena Cava

- Persistent widening ($>1.5 \times$ aorta)
 - ◆ Right sided heart failure
 - ◆ Cardiac tamponade
 - ◆ Obstruction
- Narrowing ($<1.0 \times$ aorta)
 - ◆ Usually associated with microcardia
 - ◆ Seen with shock, hypovolaemia, Addison's
 - ◆ May be artefactual due to pulmonary hyperinflation

Radiographic abnormalities of the Pulmonary Vessels

Hypovascular pattern

- ◆ Generalised reduction in vessel size
- ◆ Possible causes include
 - Hypovolaemia
 - Undercirculation of the lungs due to right-left shunting or severe pulmonic stenosis
 - Pulmonary thrombo-embolism

Hypervascular pattern

- ◆ Generalised increase in vessel size
- ◆ Possible causes include
 - congestive heart failure
 - left-to-right shunts
 - (iatrogenic) fluid overload

Changes in vessel shape

- Increased tortuosity may be seen in conjunction with vessel enlargement
 - Causes include congestive heart failure and heartworm disease
- Vessel 'pruning' is characterised by abrupt ending/reduction in size
 - Reported to be typical of pulmonary thrombo-embolism

Some Common Cardiac Conditions

Persistent Ductus Arteriosus

- Enlargement of L ventricle & atrium (generalised cardiomegaly may be seen)
- '3 knuckle' appearance on DV view due to prominence of the aortic arch, pulmonary trunk and left auricle
- Pulmonary overcirculation, dilated vessels & eventually pulmonary oedema

Pulmonic Stenosis

- Post stenotic dilation results in bulging of the pulmonary artery on DV view
- Right sided cardiomegaly
 - Rounding of the cranial cardiac border and increased sternal contact on lateral view
 - Reverse 'D' shape on DV
- May see hypoperfusion in very severe cases

Aortic Stenosis

- Often radiographically unremarkable
- +/- bulging of the aorta, left ventricular & mild left atrial enlargement

Mitral valve insufficiency

- Left atrial & left ventricular enlargement
- Pulmonary oedema and engorgement of vessels

Dilated Cardiomyopathy

- Typically large / giant breed dogs
- Marked left atrial & left ventricular enlargement
- Often right atrial & ventricular enlargement causing generalised cardiomegaly
- Left sided failure: Pulmonary venous distension and pulmonary oedema
- Occasionally right sided failure: Ascites, CdCV distension, pleural effusion

Hypertrophic Cardiomyopathy

- Cats!
- Initially radiographically unremarkable due to concentric hypertrophy
- 'Valentine' heart on DV due mainly to marked LA enlargement
- Pulmonary venous distension, patchy pulmonary oedema, +/- pleural effusion