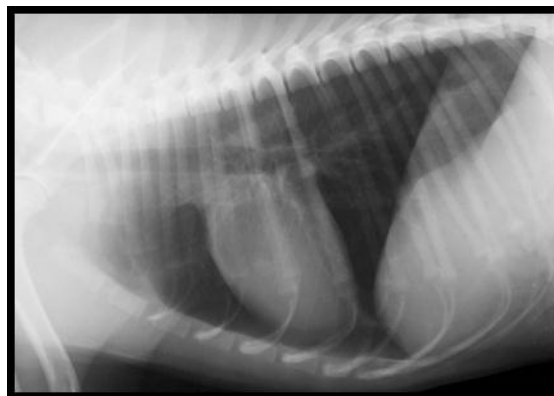


Thoracic Radiology Mini Series 2016

Session 1: Lower Airways and Lung Fields

**Esther Barrett MA VetMB DVDI DipECVDI MRCVS
RCVS & European Specialist in Veterinary
Diagnostic Imaging**

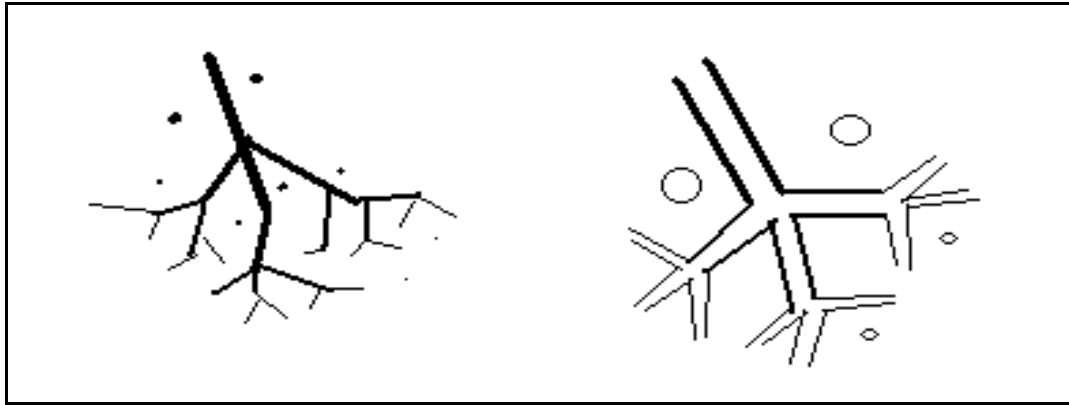


The Lower Airways and Lung Fields

Normal Anatomy

Both the dog and cat have 6 lung lobes

- ◆ Right lung: cranial, middle, caudal and accessory lobes
- ◆ Left lung: cranial (subdivided into caudal and cranial parts) and caudal lobes
 - In the cat, both cranial lungs extend to the level of the first rib
 - In the dog, the apex of the left lung can extend further cranially
 - Seen cranial to the right lung on a lateral view
 - It is usually not possible to identify the divisions between normal lung lobes, although occasionally fine pleural lines running tangential to the x-ray beam may be highlighted
- ◆ The trachea divides into the right and left mainstem (or principal) bronchi at the carina (usually at 5th intercostal space)
 - The right mainstem bronchus then divides into 4 lobar (or secondary) bronchi, one for each lobe
 - The left mainstem bronchus divides into 2 lobar bronchi
 - On a left lateral view of a dog the cranial right stem bronchus may be seen dorsal to the left cranial mainstem bronchus
 - The lobar bronchi further divide into segmental (or tertiary) bronchi
- ◆ Although the majority of the lung should consist of air (within the airways and alveoli), it is normal to see soft tissue markings corresponding to the blood vessels and the walls of the larger airways within the lung fields.
- ◆ The bronchi lie between paired pulmonary arteries (dorsally) and veins (ventrally) and should taper towards the periphery. Bronchial walls are poorly seen unless thickened or mineralised: they are most easily recognised in the perihilar areas as fine parallel lines (longitudinal section) and rings (transverse section)
- ◆ Pulmonary vessels are usually well visualised: they appear in longitudinal section as linear branching structures, & in cross-section as small round soft tissue opacities, tapering towards the periphery
- ◆ The bronchial arteries (supplying the bronchi themselves) are not seen



**Normal branching of pulmonary vessels
(NB arteries & veins normally seen paired)**

Normal tapering of the airways

Describing abnormal lungs

Accurate evaluation of the lungs and lower airways remains one of the most challenging aspects of small animal radiology. Abnormal lungs are typically described in terms of bronchial, interstitial and alveolar patterns. While this technique of pattern recognition is widely taught and used for interpreting thoracic radiographs, it is important to realise that there are some limitations. Lung pathology rarely fits neatly into one category, and mixed patterns (eg broncho-interstitial, broncho-alveolar) are more common. As well as trying to identify the patterns, it is also useful to make an assessment of the location of any changes, a general impression of the severity of any changes and an assessment of overall lung volume, taking into account the phase of respiration at which the radiograph was exposed. Radiological changes are rarely pathognomonic, and further diagnostic tests will usually be required to reach a definitive diagnosis.

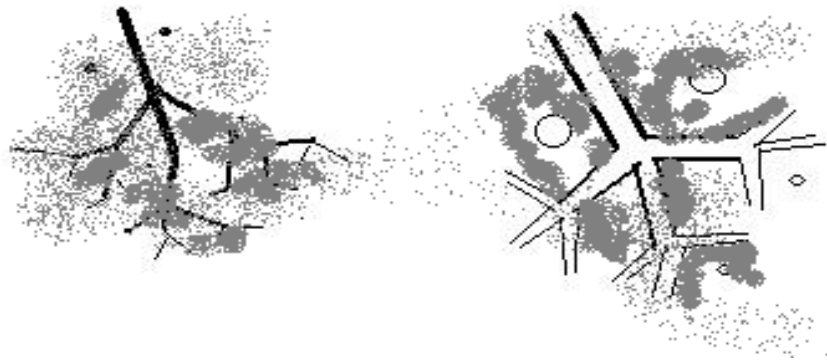Location of changes

- Where radiographic changes appear to be confined to a single identifiable lobe, then the location of these changes can be described by the lobe affected.
- However, in many cases changes are not so neatly confined. In such cases, useful descriptions of the location include:
 - Cranio- or caudo-ventral
 - Caudo-dorsal
 - 'Superimposed on the cardiac silhouette'
 - Perihilar
 - Peripheral

Lung Patterns


Alveolar Pattern

- 'Fluffy' often ill defined areas of increased soft tissue opacity which may coalesce to form larger areas of opacity, obscuring the blood vessels
 - can be localised or generalised
- Characterised by "**air bronchograms**", where the radiolucent airways are seen highlighted against a background of soft tissue opacity
- Alveolar filling occurs due to the accumulation of fluid or cells within the alveoli, most commonly due to
 - oedema
 - pneumonia
 - haemorrhage
 - neoplasia
- The distribution of changes may help to narrow down possible differentials, eg:
 - aspiration pneumonia typically results in alveolar filling of the ventral parts of the cranial and middle lung lobes
 - primary pneumonia may affect any lung lobe
 - pulmonary oedema in dogs tends to concentrate in the perihilar region: in cats it is often more widespread & asymmetrical.
 - an inhaled foreign body most often lodges in the caudal lung lobes, resulting in a localised area of alveolar filling in the dorso-caudal lung fields
- Look for evidence of lung volume change to help distinguish between alveolar consolidation due the accumulation of fluid or cells, and alveolar collapse
 - Most easily recognised on a VD radiography by looking for evidence of mediastinal shift
 - Where the alveoli are filled with fluid or cells, they take up as much or more space than when filled with air. This may result in:
 - ◆ No mediastinal shift
 - ◆ Mediastinal shift away from the consolidated lung
 - Where the alveoli are collapsed, they take up less space. This typically results in:
 - ◆ Mediastinal shift towards the collapsed lung



Alveolar infiltrate

- ◆ The vessels become obscured and the airways highlighted by the soft tissue opacity of consolidated or collapsed alveoli.




Air bronchograms

- ◆ Eventually the vessels can be completely obscured, with the lucent airways standing out against a soft tissue background.

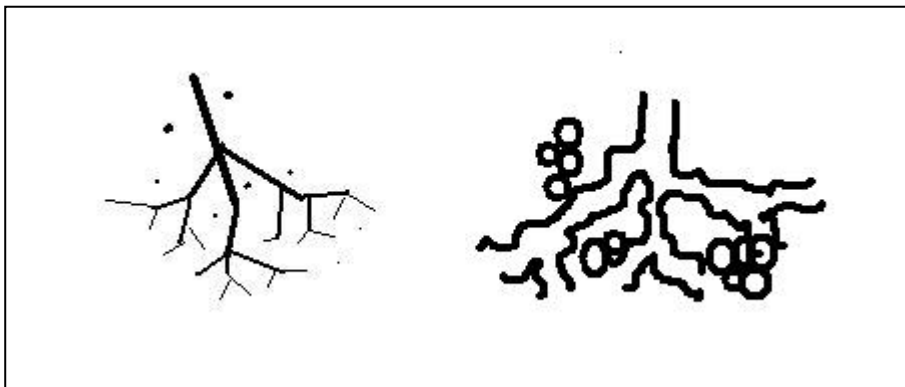
- **Partial or complete collapse** of a lobe occurs where the alveoli are collapsed and airless rather than filled with fluid or cells, eg
 - due to recumbency (especially under GA)
 - due to fluid, air or a space occupying mass in the pleural space
 - due to the occlusion of a bronchus by debris, an intra- or extraluminal mass, foreign material or lung lobe torsion

Bronchial Pattern

- Some bronchial markings are quite normal, especially in the central areas, and these tend to become more prominent with age
- Seen as "tramlines" and "doughnuts" depending on whether airways are seen in longitudinal or transverse section
- Bronchial markings may be increased
 - due to mineralisation of bronchial walls
 - ◆ normal ageing change, especially chondrodystrophic breeds
 - ◆ hyperadrenocorticism
 - due to thickening of walls and/or peribronchial infiltration
 - ◆ chronic bronchitis
 - ◆ eosinophilic broncho-pneumonopathy
 - ◆ neoplasia (eg lymphoma)
 - ◆ peribronchial oedema (eg due to left sided heart failure)



- Bronchiectasis occurs where the airways become abnormally dilated +/- saccular in appearance
 - May be congenital or acquired
 - Most commonly affects cranial lung lobes

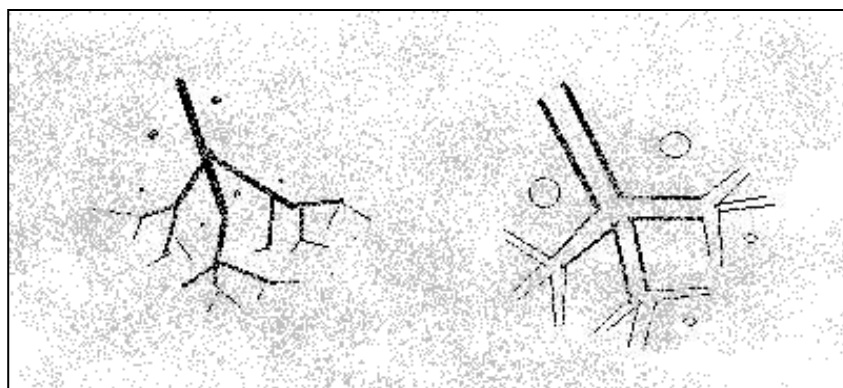


Interstitial Pattern

- ◆ Probably the hardest to define!
- ◆ The term 'interstitium' refers to the general background opacity of the lungs
 - composed of the alveolar walls, smaller blood vessels, lymphatics, nerves and connective tissue
- ◆ An interstitial pattern is seen when this supporting tissue becomes infiltrated with fluid, cells or fibrous tissue or with nodular lesions arising from the interstitial tissue
- ◆ Appears as either
 - A diffuse interstitial pattern: fine reticular or hazy opacity throughout the lung fields, partially obscuring the normal broncho-vascular pattern
 - A miliary (micro-nodular) interstitial pattern.
 - A nodular interstitial pattern

Diffuse Interstitial Pattern

- ◆ Any pulmonary disease 'in transition' (ie developing or resolving) may present with increased diffuse interstitial opacity, making the list of possible differentials extremely long! Important differential diagnoses include
 - interstitial oedema
 - interstitial pneumonia (allergic, viral)
 - interstitial haemorrhage
 - pulmonary fibrosis
 - diffuse neoplasia (eg lymphoma)
- ◆ An increase in interstitial opacity can be mimicked by:
 - poorly inflated lungs
 - overlying fat in an obese animal
 - underexposure



Miliary Interstitial Pattern

- ◆ radiographically not individually visible
- ◆ superimposed nodules can summate to give the appearance of multiple small nodules in diameter
- ◆ typically generalised changes affecting all lung lobes due to widespread haematogenous +/- lymphatic dissemination of neoplastic or inflammatory cells
- ◆ differential diagnoses include:
 - miliary metastatic neoplasia
 - pulmonary lymphoma
 - haematogenous bacterial pneumonia
 - miliary granulomata
 - TB

Nodular Interstitial pattern

- ◆ Nodular opacities tend to be circular, and vary widely in their size, number and distribution.
 - The most likely differential for multiple pulmonary nodules >5mm diameter is metastatic neoplasia.
 - Larger nodules will be more opaque
 - Eosinophilic broncho-pneumonopathy, angiostrongylus and (less likely) multiple pulmonary abscesses, granulomas, cysts or haematomas may also present as a nodular lung pattern
 - Spherical nodules with a diameter <5mm are unlikely to be seen radiographically, unless there is summation or co-alescence of a great number of smaller masses
 - ◆ Opacities less than 5mm in diameter are therefore more likely to be mineralised opacities or end on vessels
 - Compare the diameter with that of adjacent vessels seen in longitudinal section
 - Remember that superimposed nipples, end on blood vessels and overlying skin masses can mimic soft tissue pulmonary nodules

Lung Masses

- ◆ Lung masses are defined as being greater than 4cm in diameter
 - Lesions less than 4cm in diameter are described as nodules
- ◆ Differential diagnoses for lung masses include:
 - Neoplasia
 - Primary neoplasia most commonly presents as a solitary nodule or mass
 - Metastatic neoplasia is more likely to be seen as multiple smaller masses or nodules
 - Abscess
 - Granuloma
 - Haematoma
 - Cyst

Increased pulmonary lucency

Although most thoracic disease is recognised on radiographs as areas of increased opacity, in a few situations, abnormally lucent pulmonary tissue may be seen

- ◆ Differential diagnoses for generalised pulmonary hyperlucency include:
 - Artefactual: eg overexposure, iatrogenic overinflation
 - Hypoperfusion
 - Pneumothorax
 - Generalised pulmonary emphysema with air trapping
 - Comparison of inspiratory & expiratory films may be useful
 - Horizontal beam radiography may show lack of collapse of the dependent lung due to air trapping
 - Check your Local Rules to see if horizontal beam radiography is permitted in your practice
 - Take extra care with radiation safety!!
- ◆ Differential diagnoses for localised pulmonary hyperlucency include:
 - Lung bullae
 - Haematocysts (usually traumatic in origin)
 - Cavitory masses
 - Neoplasia
 - Abscess
 - Localised emphysema
 - Pulmonary thrombo-embolism