



Cardiac Ultrasound Online 'Mini Series'

**Session 2&3: Acquired Heart
Disease &**

**Doppler Echocardiography and
Congenital Heart Disease**

Mark Patteson

MA VetMB PhD DVC CertVR MRCVS

RCVS Specialist in Veterinary Cardiology

HeartVets

Advanced techniques

Subjective assessments in echocardiography

Valve motion

Because M-mode produces a near continuous image and is not limited by frame rate, it is very useful for identifying rapid motion. It can also be used quantitatively to produce indices of systolic and diastolic function from the timing and rate of motion of the valves, septum or free-wall. Despite its potential uses, this is seldom done in clinical practice.

The motion that is most often interpreted is that of the valves, particularly the mitral valve. This produces a series of defined points. The E point is that of the maximal motion of the anterior mitral leaflet towards the IVS and marks the end of early diastolic filling. It is followed by the F point as the leaflet closes in the tail of this early diastolic flow. This is followed by the A point at which the valve is again opened, this time by atrial contraction. The next two points are the C point at which the valve is closed at the beginning of systole and the D point at which the valve opens at the beginning of diastole. The relevance of the relative size of the E and A points, and the EF slope are discussed below. Another useful measurement derived from the M-mode measurement of mitral motion is the end-point to septal separation (EPSS). This is a useful measurement, especially in cases where FS% is potentially unreliable. An increased EPSS is associated with an increase in LV volume and a relative decrease in stroke volume, i.e. systolic dysfunction. It is very important that the M-mode cursor bisects the IVS perfectly for this to be valid. Normal measurements in a dog are usually quoted at <6mm, <5mm in a cat.

Because of its almost continuous signal, M-mode is especially good at detecting high frequency motion that may not be apparent from 2DE. High frequency valve motion can be identified in aortic regurgitation, and is a sensitive method of confirming the presence of regurgitant flow. The high frequency vibration result from the AML being struck by the regurgitant jet, and the AoV may also vibrate.

Abnormal motion of the anterior mitral leaflet can be seen in animals with dynamic obstruction of the LVOT. This is called systolic anterior motion (SAM), and is common in cats with HCM (but can also occur in dogs). The AML gets sucked into the LVOT by a Venturi effect, resulting in it doming towards the IVS between the C and D points of valve motion.

Dynamic outflow obstruction can also result in abnormal motion of the semi-lunar valve, which will have a notch in its motion caused by the mid-systolic reduction in flow. This may be more easily seen

on the Doppler signal.

Assessment of wall motion

Valuable information can be obtained from qualitative or quantitative measurement of wall motion. In human medicine this is very important as coronary heart disease can lead to localised areas of ischaemia and asynchronous motion. This is known as dyskinesia. Dyskinesia is occasionally seen in small animals and is associated with myocardial disease. More common wall motion abnormalities are associated with right ventricular pressure or volume overload. In some animals, especially but not exclusively those with myocardial disease, the interventricular septum flaps between the LV and RV. This gives the impression of increased contraction, but in fact the IVS can be acting like a sail between two areas of different pressure. It can result in FS% values which give the impression of contractile function which considerably exceeds the true contractile state of the LV.

With marked pressure or volume overload (usually both) of the RV the septum can be pushed into the LV. This implies an RV pressure close to systemic (i.e. nearly 100mmHg), and is usually seen with pulmonic stenosis or severe pulmonary hypertension. The motion of the IVS is towards the LVFW in diastole, and can be away from the LVFW in systole. This is known as paradoxical septal motion.

Another important example of abnormal wall motion is the motion of the RA wall in animals with cardiac tamponade. The wall flaps in and out and collapses to occlude the RA lumen. With any PE you can see some RA wall motion, simply because you can now identify the wall, but complete collapse does not occur unless tamponade is present.

With severe aortic regurgitation the IVS will continue to move towards the RV throughout diastole. High frequency vibration of the IVS may also occur as it is struck by the regurgitant jet, just as occurs with the AML.

Shape of the ventricles

The shape of the ventricles varies with species and breed, but can also be affected by volume overload (or volume depletion). Volume overload results in a more rounded LV apex.

Proportional size of ventricles

“Eye-balling” the proportional size of ventricles is inevitably one of the first impressions gained from an echocardiogram, and although this is no substitute for accurate measurement, there are times where it may be all that can be reliably produced, and with experience it provides much of the useful information from echo. Thus the marked dilation of the LA in a right parasternal long-axis view may be as reliable a method of estimating the severity of mitral regurgitation as any Doppler technique.

Proportional thickness of ventricles

Likewise to the chamber size mentioned above, the wall thickness may immediately strike one when the echo is performed. With right-sided problems there is no accurate measurement method and subjective impression of dimensions is all that can be obtained.

Bowing of the septa

As discussed above, the IVS may move abnormally with RV abnormalities. Likewise animals with acute marked LV overload may have an IVS that bows out towards the RV during diastole. The position of the atrial septum can also be affected. Usually this has a concave aspect on the left atrial side (convex within the RA), but increased RA pressure may reverse this.

Structural abnormalities

Most structural abnormalities are identified from 2DE. This requires a detailed knowledge of anatomy and perfect selection of imaging factors, for example a gain that is set too high may give the impression of a thickened valve. The point at which a valve is perpendicular to the beam will also look thicker on 2DE and M-mode than other points where it may be tangential to the plane of the beam and therefore produce fewer specular echoes.

Mass identification

Intracardiac masses are relatively rare in small animals. Thrombi may be seen in the LA or occasionally the LV, especially in cats with HCM or RCM. Tumours most commonly result in pericardial effusions (see previous notes). Mural masses are rare, but intracardiac lymphoma occurs in both cats and dogs, and rhabdomyosarcomas and secondary metastatic tumours have also been reported.

Contrast echocardiography

Contrast echocardiography is a useful technique, particularly if Doppler is not available. Selective studies can be performed with the use of intra-cardiac catheters; however, non-selective echo-contrast studies are also useful and are simpler to perform. Non-selective investigations can be used to show movement of regurgitant blood across the tricuspid valve, or jets of blood flowing through congenital shunts. A video recording is very helpful for later replay and analysis.

A number of different contrast agents have been used, but a convenient medium which provides very good contrast is a plasma volume expander such as Haemaccel (Hoechst UK Ltd.). This must be agitated to produce micro-bubbles. This is easily achieved by repeatedly passing the solution from one syringe to another via a three-way tap. Around 2-10 ml of agitated solution are injected rapidly through a catheter into the jugular vein. Contrast is seen filling the right side of the heart with a dense white "cloud". It does not pass through the pulmonary capillaries and therefore does not opacify the

left side of the heart unless a right-to-left shunt is present.

Systolic time intervals

STIs are potentially informative but are very dependent on correct timing and accurate positioning of the cursor for m-mode/Doppler is critical.

Systolic time intervals are seldom measured in clinical cases but can be a very sensitive measurements reflecting changes in cardiac loading and function. However, as with other non-invasive measurements they cannot separate the factors of contractile function from loading conditions. Originally these were measured from a phonocardiogram, carotid arterial pulse pressure and the ECG, but they are more accurately measured from the ECG and echo. They can be measured from Doppler identification of flow timing.

The **pre-ejection period** (PEP) is the period from the beginning of electromechanical systole (signified by the onset of the Q wave) to the opening of the aortic valve (for LV STIs), measured from the M-mode echo.

The **ejection period** (ET) is the time that the aortic valve remains open (or the duration of flow).

Total electromechanical systole is the period from the beginning of electromechanical systole to the closure of the aortic valve, i.e. PEP + ET.

The **PEP:ET ratio** is an attempt to remove the effects of factors such as heart rate and end-diastolic aortic pressure (part of afterload). The higher the PEP:ET ratio, the worse the systolic function.

Relaxation time

Just as there are systolic time intervals, equivalent factors can be derived for diastolic events.

Doppler Echocardiography

Doppler echocardiography is used to provide information about blood flow, following evaluation of the structure and the size of the heart using 2DE and M-mode studies. A thorough Doppler examination requires rigorous technique and is extremely time consuming. Colour-coded Doppler reduces the time required for Doppler examinations and makes them easier to perform, but has the same physical limitations and is extremely expensive. Doppler is most useful in animals with congenital heart disease, when it can be used to quantify the effects of disease. It can also be used to identify and then to "map out" jets of regurgitant blood (and the area of the origin of the jet) as a rough guide to the severity of the valvular incompetence. The use of Doppler has largely removed the need for cardiac catheterisation.

The Doppler equation

$$V = \frac{C * FD}{2Fo \cos \phi}$$

Where :-

- V = Velocity
- C = Speed of sound in soft tissue
- Fo = frequency of insonating beam
- FD = Change in frequency (Doppler shift)
- COS ϕ = angle of insonating beam

Pulsed wave Doppler

- Single crystal transmits & receives signal
- Must wait to receive returning signal before transmits next signal
- Specific sampling site is chosen
 - Provides means of detecting depth at which returning signal has originated
 - Echoes from moving blood arrive at transducer during discrete time interval corresponding to vessel's depth
 - Only echoes during this interval are accepted
 - 2-D image is periodically updated

Continuous wave Doppler

- Two crystals in the transducer, one continually transmits, one continually receives
- Can accurately measure high velocities as seen with stenoses & regurgitations

Colour flow Doppler

- PW Technology
- Colour coding of *average* velocity
- Superimpose on 2-D or M-mode images of the heart
- Flow towards transducer is usually coded red
- Flow away from the transducer is coded blue
- Increasing velocity is coded in lighter shades of the basic colour or as changing hues of the colour
- Turbulence displayed as a mosaic pattern with a variance colour added (green)

Basic issues:

- Alignment – good alignment is fundamental
- Clarity of signal
- Overgained signals potentially lead to overestimation of velocities – less of a problem with better equipment
- “Space invader” technique – how accurately can you draw a VTI envelope? Practice improves cursor placement.

Jargon busting:

Sample volume: the area from which pulsed wave Doppler flow is detected, determined by the gate on the time at which samples are analysed.

Aliasing: Occurs if Doppler shift exceeds twice the PRF i.e. inadequate sampling rate cannot keep pace with the rapidly moving structures.

Nyquist limit: aliasing if $PRF < 2 \times$ frequency shift

- Frequency shift (f_o) affected by frequency and PRF
- greater depth (D) gives aliasing at lower velocities

Maximum velocity before aliasing

$$V_{Max} = \frac{(1540 \text{m/sec})^2}{8f_o \times D}$$

To reduce aliasing:

- Use lower frequency transducer
- Move the baseline up or down
- Bring sample point closer to transducer
- Use high PRF Doppler
- Use CW Doppler

Envelope: The display of the velocity of flow. In laminar flow the majority of the red cells will be moving at the same velocity so there is line resulting from a strong signal at a specific frequency. Where there is disruption of flow the envelope will be disrupted, known as spectral dispersion or disturbed flow. A clean envelope can also be lost if the sample volume and line of the Doppler signal are not correctly positioned. There is no envelope with CW signals.

Using Doppler

Colour flow settings:

Colour flow mapping is used to localise jets and abnormal flow, but is only semi-quantitative at best. Quantitative estimates of regurgitation are based on area of the jet, width of the jet and especially width of the base of the jet. This is all somewhat gain dependent. A quantitative method of mitral regurgitation is to use the PISA method looking at flow convergence on the ventricular side of the mitral valve. This is not yet widely used in clinical practice.

Other tips are:

- Chose a colour flow map with a variance setting
- Reduce the 2DE image gain
- Reduce the 2DE sector angle
- Use the smallest colour ROI that you can get away with
- Remember that some colour flow machines, transducers and settings are designed for low velocity flow

Quantitative Doppler

We use PW or CW Doppler to make quantitative measurements. Usually CW is a better signal but does not give the localisation of PW. Accurate use of PW or CW is entirely dependent on correct alignment with flow.

Pressure gradient estimation

There are a number of presumptions based on the physics of Doppler. What is actually measured by the machine is the frequency shift of the sound. The velocity is estimated from the frequency shift by the Doppler shift equation.

Pressure estimation

The pressure gradient can then be derived from a known or supposed pressure using the Bernoulli equation, so for example a velocity across the aortic valve is rounded off to be compared with a zero pressure, i.e. a 4 m/sec jet indicates a pressure gradient across the valve of 64mmHg, where as 4 m/sec velocity jet across a VSD would infer an RV pressure of around 36 mmHg if the left ventricular systolic pressure was around 100 mmHg.

Modified Bernoulli equation

$$P_1 - P_2 = 4 (V_2^2 - V_1^2)$$

P_1 = pressure proximal to lesion

V_1 is close to 1 m/s

Pressure *gradient* = $4V_2^2$

Shape of envelope

There are occasions on which the flow does not have a normal shape envelope. Usually there will be a rapid rise in velocity, followed by a less rapid fall. On occasions such as dynamic obstruction of the LVOT there may be a step in the flow, or with pulmonary hypertension there may be a notch in the RVOT outflow profile.

Shunt ratios

Shunt ratios, the ratio of pulmonary to systemic flow (QP:QS) can be determined if an accurate assessment of the output of the LV and RV can be made. For example, in an animal with a PDA, the flow through the LV will be greater than that through the RV because blood is shunted from the aorta into the PA so that it will return to the left side, without flowing through the right side. Thus if VTIs are measured for PV and AoV flow then the relative difference in output can be calculated. The same principle would apply with a VSD, but here the L-R shunt occurs within the heart and so the shunt ratio must involve measurement of AV flow. This is problematic because measurement of the valve area of AV valves is much more difficult. Other problems are the presence of additional abnormalities such as aortic or pulmonary stenosis, mitral regurgitation and pulmonary artery dilation in an animal with a PDA.

Doppler indices:

Acceleration time: The acceleration time is a systolic time interval which measures the rate at which peak flow is reached, and this is largely dependent on contractile force and afterload.

Velocity time integral (VTI): This is the area within the envelope which is proportional to the volume of flow. To calculate the volume flow, the area of the aperture (eg aortic valve area) is measured from 2DE and the formula **volume flow**: = VTI x area is to calculate the stroke volume and hence derive cardiac output values.

Rate of acceleration: Like acceleration time this is largely dependent on contractile force and afterload.

E wave and A waves: The E wave reflects the velocity of the flow in early diastole which is affected by the volume of flow, the aperture through which it flows and the diastolic function of the LV. The A wave is affected by the same factors and atrial function, so it is absent with atrial fibrillation. The ratio of E:A waves can reflect the diastolic function. It is especially useful in cats with HCM.

A practical difficulty is that at high heart rates, the E and A waves tend to merge. However, when they can be seen in normal animals the E wave is the larger of the two. In HCM there may be poor relaxation due to poor lusitropic state. In these animals the size of the E wave will reduce and the proportion of the A wave, and its absolute velocity, may increase. Where there is restrictive physiology due to physical limitation of relaxation, for example with fibrosis of the ventricle, the E wave is much the larger of the two because the ventricle cannot take any extra flow at the end of diastole from atrial contraction. What in fact in many animals occurs is a combination of abnormal relaxation and restriction of diastolic expansion of the ventricle, in which case a pseudo-normalised pattern of flow may be seen, where the E wave and A wave are relatively normal.

EF slope: This is a very important measurement in humans in which mitral stenosis is common. By measuring the VTI and known SV information one can derive on formation inferring the area of the valve, and some echo machines will have this as a pre-set function in the cardiology package. In veterinary medicine, it is most useful in English Bull Terriers in which mitral stenosis does occur. The flatter the EF slope the worse the stenosis.

Half time of AI jets: Severe AI results in a rapid rise in LV diastolic pressure and the diastolic pressure gradient across the aortic valve falls rapidly. This means that the velocity of the AI jet drops rapidly. Conversely, mild AI resulting in little flow has little effect on diastolic pressure and the pressure gradient changes little, hence the slope of the jet is very flat. This can be measured as a half-time, the time taken for the velocity of the jet to fall by half. The higher the figure the less severe the regurgitation. In fact AI has to be severe for this to be a useful measurement.

LVOT/Aortic measurement:

Subcostal best and is possible in vast majority of patients

Variable measurements due to sinus arrhythmia and excitement

Possible to identify the wrong jet - can pick up "stray" MR

RVOT/PA measurement

Sometimes difficult to get left cranial view because of lung interference.

Difficult to get so well aligned from right.

VSD jets

Some jets bounce off walls leading to confusing direction .

Can be difficult to align with the jet especially if it is very cranially directed.

Mitral regurgitation jets

Be very cautious about estimating LA pressure from measurement of MR velocity. Subtraction issues amplify error and a very small inaccuracy in velocity estimation leads to a very substantial change in LA pressure estimates.

TR, PR – often eccentric jet and can be easy to be poorly aligned and then underestimate pressure gradients.

E and A waves

Affected by: cycle length
 exact positioning of sample volume
 respiration

Can be difficult to get good alignment especially if there is marked cardiomegaly and so may underestimate velocities. Substantial CV% and very user dependent.

Pulmonary venous flow

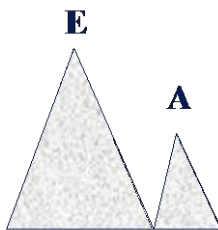
Assessment of pulmonary venous flow gives information about diastolic function. However the technique is not easy and there is a large coefficient of variability which means, in the author's opinion, that this is a research tool rather than a clinical tool at present.

Diastolic functional indices.

Assessment of diastolic function is more complex than systolic function. Many factors contribute to the way in which the left ventricle fills, including LV myocardial tissue characteristics, wall thickness, systolic function, presence of ischemia, left atrial function, preload, rhythm, RV filling, and pericardial restraint (amongst others). The most important factors can be considered to be:

- LV relaxation
- LV compliance
- LA pressure / function

Some indication of diastolic filling characteristics can be obtained from transmitral flow patterns.



Normal

Transmitral flow may be categorized as:

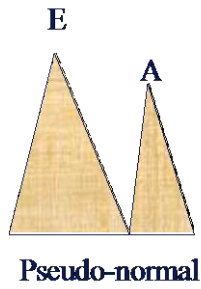
Normal (most filling occurring in early diastole)

Delayed relaxation pattern (most filling occurring in late diastole, when relaxation is complete)

- Prolonged E wave deceleration time
- E:A ratio < 1.0
- May be seen in normal older animals
- Common in cats with HCM

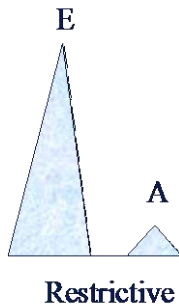
Pseudo-normal (combination of delayed relaxation and increased atrial pressures)

- Likely if large LA but “normal” transmitral flow pattern
- E:A ratio > 1.0, < 2.0
- Combination of abnormal relaxation with high LA pressures and/or reduced LV compliance
- Can be difficult to distinguish from normal filling- pulmonary venous flow, other advanced Doppler techniques can be used



Restrictive (increased LA pressures with stiff LV)

- Seen with LA pressure \square severe myocardial disease and
- E:A ratio \gg 2.0
- Combination of high LA pressures and/or reduced LV compliance
- Ominous prognostic sign



In some cats there will be echo evidence of infarcts, with areas of mottled or very intense increased echogenicity within the myocardium, often in the sub-endocardial region. Intracardiac lymphoma is another possible localised abnormality which is generally but not always a circumscribed localised hypoechoic region.

ACQUIRED HEART DISEASE:

The novice echocardiographer may be comforted by the fact that acquired cardiac disease is often much simpler to diagnose echocardiographically and accounts for around 95% of cases seen.

Valvular lesions:

The most significant echocardiographic feature of valvular lesions is their **effect on cardiac dimensions and performance**, rather than the identification of abnormal valves themselves. The apparent thickness and echogenicity of valves is markedly affected by the settings on the machine. Valves normally have areas which are more echogenic than others because they are more perpendicular to the line of the beam. For example, the tip of the left coronary cusp of the aortic valve often looks thicker and more echogenic than the rest of the valve from a right parasternal view. Flail leaflets result from ruptured chordae tendineae to the AV valves and torn semi-lunar valves. A portion of a valve can be seen curling back into the preceding chamber. If the flail is not entirely in the line of the beam only an echogenic dot is seen in the LA during systole. A cine-loop facility or good quality video for slow replay are very helpful in identifying prolapse and flail because they are best appreciated on 2DE.

Endocardiosis

Endocardiosis results in thickened valves and in some cases chordae tendineae, and often in prolapse (billowing) or flail of the valves. The lesions are often dramatic in dogs. The most significant part of the examination is to assess the degree of volume overload represented by the dilated LV and LA (or RA and RV with tricuspid valve endocardiosis). One may also identify ruptured chordae tendineae and in some cases left atrial tearing. Most cases have an increased FS% due to the lack of resistance to regurgitant flow, so if this is not apparent then a degree of myocardial disease may be present.

Although the use of CFD produces some very aesthetically pleasing images, it is essential that the 2DE and M-mod echo images are recorded first and with pedantic accuracy. However it is possible to gain additional qualitative, semi-quantitative and quantitative information from Doppler to complement this. The width of the jet at its origin (*vena contracta*) and to a lesser extent within the left atrium reflect the size of the regurgitant flow. In addition the flow acceleration towards the leak which can be assessed on CFD is an indication of the size of the jet. Measurement of the velocity of the jet and from it an estimation of the pressure within the left atrium is fraught with difficulty. The measurement will produce a large number for the pressure gradient (eg 110 mmHg difference) and then this is deducted from another slightly larger number (LV pressure assumed to be 120 mmHg) then the difference is a very small number with a lot of variation due to technical limitations. So a

slight underestimate of the pressure gradient will result in a estimate of the left atrial pressure which can be factors greater than the real value.

When there is marked volume overload the velocity and some cases the duration of the E wave will be increased because of the large volume of blood that is entering the volume overloaded LV from the dilated LA.

A more valuable use of spectral Doppler is to measure the velocity of tricuspid regurgitation to estimate RV and therefore (in the absence of an outflow obstruction) estimate systolic PA pressure. This involves deducting a small number from a large number and is therefore very much less prone to significant error. If the RA pressure is taken as just over zero then a TR jet of <2.8 m/sec will be associated with an RV pressure of < 30 mmHg. It is possible to pick up TR in almost all dogs with CDMVD provided that a low frequency probe is used, and identification of pulmonary hypertension can affect both treatment and prognosis.

Endocarditis

Endocarditis is relatively rare, nonetheless echocardiography may be the only way to rule out the condition in animals with pyrexia of unknown origin. The most striking feature is the large vegetations found in many animals with endocarditis, most commonly affecting the aortic valve. However, in some cases the vegetative lesions are fairly small and can be difficult to distinguish from endocarditis if they affect the AV valves. Almost invariably the lesions will result in valvular incompetence and regurgitation will be identified on Doppler echo.

Myocardial disease

Myocardial disease comes in a variety of forms, and is the most commonly recognised cardiac condition of exotic species such as ferrets. It is possible to split myocardial disease into numerous different varieties, those below are the useful broad-term categories.

Dilated cardiomyopathy

DCM is most common in giant breed dogs but also occurs commonly in Cocker and sometime Springer spaniels, and can be seen in any breed. The prime echocardiographic features are LV and LA dilation, and a poorly motile heart (low FS%). There is also an increased E point to septal separation. Bear in mind that the FS% can be lower than quoted ranges in large breed dogs. There is therefore a grey area for difficult diagnosis. DCM is now uncommon in cats but still occasionally occurs even in cats with taurine sufficient diets. The availability of echo is the key to diagnosing DCM and is one of its most useful features in clinical practice, and usually one of the easiest diagnoses.

Most dogs with DCM develop MR to some extent or other. In some cases it is difficult to say whether there is an element of primary valvular disease as well as myocardial failure. This may or may not be of clinical significance. In those animals with primary myocardial disease the jet is often central, while in dogs with degenerative mitral valve disease it is often at an oblique angle, running down the atrial walls. In severe myocardial failure the velocity of the MR may fall, however the technical inaccuracies of its measurement make interpretation of this change fraught with difficulties and unreliable. The development of pulmonary hypertension in these cases is less frequent than in primary DMVD.

Feline cardiomyopathy

DCM in cats is now rare. The prime echocardiographic features are striking LV and LA dilation, usually slightly less severe RV and RA dilation and a poorly motile heart (low FS%). There is also an increased E point to septal separation.

Do not interpret these features in sedated animals.

Hypertrophic cardiomyopathy

HCM is common and is characterised by a thickened LV. This may affect different parts of the LV to differing degrees. Because there is reduced compliance of the LV there may be LA dilation, and when this occurs then clinical signs are most likely to be noticed.

- IVSd and/or LVFWd > 6.0mm
- Often dilated LA (this is the most important feature)
- Often SAM
- Thrombus (or 'smoke') may be present in L auricle

HCM is now the most common cause of a cardiac murmur or a gallops sound in cats, and the changes of HCM may be absent on thoracic radiography or even ECG. There is therefore a case to perform echocardiography on every cat with a murmur or gallop, in order to establish the degree of cardiac compromise and LA dilation so help decide on whether to treat and what to use.

HCM is very rare in dogs.

Restrictive / moderator band cardiomyopathy

Restrictive cardiomyopathy occurs in some cats and is characterised by an irregular often heterogeneously echogenic LV with marked and LA dilation.

- severe LA, RA dilation
- midventricular bands, or endocardial fibrosis in some forms
- LV may appear relatively normal in other forms
- Thrombi common

SAM:

In late systole, the anterior mitral leaflet is drawn across towards the LVOT towards the stream of blood being ejected. This creates obstruction to further ejection of blood, and also results in mitral regurgitation. This is more likely to occur with increased sympathetic drive.

Spontaneous Contrast

In cats with marked left atrial enlargement, a grey haze may appear due slow intra-cardiac blood flow. This often precede thrombus formation. Thrombi are often found in the left auricular appendage but can be in the middle of the left atrium and may even prolapse into the mitral annulus. Cats may develop FATE without previous echo evidence of intracardiac thrombi.

Diastolic functional indices.

Assessment of diastolic function is more complex than systolic function but is very useful especially in feline cardiomyopathy. These issues are addressed earlier in the course notes.

Myocarditis

Some dogs appear to get a myocarditis and in some cases this will result in reduced functional indices such as FS%, and a mottled increased echogenicity within the myocardium. However as this is so dependent on the gain settings and other technical factors it should be diagnosed with due caution. Myocarditis and areas of ischaemia are increasingly recognised in feline cardiomyopathy.

Pericardial Disease

Pericardial disease in dogs is fairly common. The most common finding is a pericardial effusion, which on echo appears as an anechoic band surrounding the heart, between the moderately echogenic myocardium and the echogenic pericardium. A pericardial effusion becomes most significant when it results in a sufficiently high pericardial pressure to restrict venous return, a situation

called tamponade. The first echocardiographic sign of tamponade is collapse of the RA, when it is more severe it may cause partial collapse of the RV during diastole.

The two most common causes of a PE in dogs is an **idiopathic** effusion, and a **neoplastic** effusion. The fluid aspirated in these cases is of very little value in reaching a diagnosis, so a detailed echocardiographic examination is essential. It may also be a helpful guide to drainage. Concentrate on the dorsal aspects of the right atrium and around the aortic arch. Beware diagnosing the “ear-shaped” right atrial appendage as a tumour, it will float away from the right atrium and be visible in many PEs and is normal. If you identify a mass on the right atrial wall it may be a **haemangiosarcoma**, or around the aortic arch may be a **chemodectoma**. **Mesotheliomas** are more difficult to identify, and however experienced you are you may miss some tumours only to find them at subsequent examinations.

Strands of fibrin may appear as echogenic fronds within the pericardial space in bacterial pericarditis (rare). Very echogenic "particles" may result from gas bubbles indicating the presence of an anaerobic infection. These findings indicate the need for aggressive treatment even if tamponade has not occurred.

Always ultrasound the heart to rule out a pericardial effusion if you have diagnosed a splenic haemangiosarcoma, radiography may not detect small pericardial effusions (PEs).

Constrictive pericarditis is much more difficult to diagnose echocardiographically. The pericardium may appear thickened. If there is sufficient fibrous tissue, restriction of diastolic flow may occur, with flow checked midway through early diastolic filling resulting in a step in the early diastolic motion of the MV on the M-mode trace.

CONGENITAL HEART DISEASE:

Aortic stenosis

Mild aortic stenosis is very common in Boxers and it is increasingly recognised in other breeds including Golden Retrievers and Newfoundland retrievers. In mild cases little will be seen on 2DE. In more severe cases the lesion is usually subvalvular, and a ridge of tissue will be seen below the valve. Take care not to create this impression artefactually by taking an oblique plane through the base of the interventricular septum. The most sensitive indicator of aortic stenosis is Doppler echocardiography. Ideally this should be performed from the sub-costal view (best alignment) with steerable CW Doppler (large distance to the valve and may have high velocities). In more severe cases, there will be LV hypertrophy, with increased echogenicity of the wall and especially the papillary muscles. This must be distinguished from LVH secondary to hypertension or due to hypertrophy cardiomyopathy (see below). The more severe the hypertrophy, the worse the obstruction. In more severe cases the lesion may also result in aortic incompetence, and a jet of regurgitation may be seen on Doppler.

Doppler investigation is very useful to estimate the pressure gradient and grade the severity of the lesion. The difference between high velocity flow in a normal animal and flow through a diseased LVOT can be difficult. Velocities around 2.00 – 2.25 m/sec are probably indicative of mild AS, while severe cases have velocities over 5 m/sec. Myocardial failure and concurrent mitral regurgitation may affect these figures.

As with all CHD, don't stop when you have identified problem A, make sure that it is not part of a complex anomaly.

Pulmonic stenosis

Pulmonic stenosis is a relatively common lesion, and its severity may be difficult to judge from clinical examination alone. It can also be difficult to distinguish from, AS on clinical exam. The lesion may involve the valve itself (echogenic and poorly moving) or the annulus of the valve. Discrete subvalvular stenosis is uncommon and supra-annular stenosis are rare. The most sensitive indicator of pulmonic stenosis is **Doppler** echocardiography. This can be performed from the left or right parasternal view with steerable CW Doppler (may have high velocities), although from the left side the distance to the valve is small and aliasing is less of a problem with PW, and alignment is often easier. In more severe cases there will be RV hypertrophy, with increased echogenicity of the wall and especially the papillary muscles. This must be distinguished from RVH secondary to pulmonary hypertension, but this is rare. In some cases there will be a post-stenotic dilatation, but this must be distinguished from other causes of pulmonary dilatation such as a PDA or pulmonary hypertension.

Doppler investigation is very useful to estimate the pressure gradient and grade the severity of the lesion. These can be arbitrarily divided into:

- mild < 50mmHg
- moderate 50-100 mmHg
- severe >100 mmHg

PDA

In many animals with a PDA the diagnosis is obvious from the murmur, however as a PDA can be part of a complex anomaly it is worthwhile doing an echo. 2DE will show a degree of left atrial and left ventricular dilation, depending on the size of the shunt. The pulmonary artery can be seen to be dilated and in severe cases this can be dramatic. In a few cases the ductus itself can be identified. This is much easier with the aid of colour-flow. Doppler of the pulmonary artery will show continuous turbulent flow. Because of the left to right shunt mitral inflow and aortic outflow velocities will be raised. This can make interpretation of the presence of stenosis of these valves complex and difficult.

Mitral dysplasia

Mitral dysplasia is increasingly commonly recognised, usually in large breed dogs such as the Great Dane, Golden Retriever and Labrador Retriever. English Bull Terriers (EBTs) also have their own variety of the condition. The condition is one of the most common congenital defects in cats.

Echo may demonstrate thickened valves or abnormal chordae tendineae or papillary muscles. There may be left atrial and ventricular dilation secondary to mitral regurgitation, which may be demonstrated using Doppler. In older animals it can be difficult to distinguish acquired from congenital mitral valve disease. EBTs have their own form of the disease with a considerable stenotic element, which may lead to a huge left atrium and a valve that appears to move very little, even if it is not very thick. The M-mode motion of the valve is grossly abnormal, with a very flat E-F slope and in some cases pronounced A point excursion.

Tricuspid dysplasia

Tricuspid dysplasia is an uncommon condition most often seen in the Labrador Retriever. The TV may look thickened, with abnormal chordae, and there is usually a very dilated RA and a dilated RV, with paradoxical septal motion in severe cases. Doppler examination will show marked tricuspid regurgitation.

Ventricular septal defects (VSDs)

VSDs are a relatively common defect, and are recognised as a gap between the base of the IVS and the base of the aorta (the most common site). It is usually seen in the long-axis view but may be more easily seen in the short-axis view or oblique views in some animals. In some cases the defect is very small and may be detected using Doppler. Colour-flow Doppler allows identification most easily. 2DE will show a degree of left atrial and left ventricular dilation, depending on the size of the L-R shunt. In a few cases there will be changes in the right ventricle and the pulmonary artery may be dilated. Doppler echocardiography is useful for making quantitative assessment of the pressure gradient between left and right ventricle, which is a good guide to prognosis, although it can be difficult to align the beam accurately with the jet.

Atrial septal defects (ASDs)

ASDs are a relatively infrequently recognised defect. They are recognised as a gap in the septum and most easily seen in the right parasternal long-axis view or a sub-costal view. It is important not to mistake artefact for an ASD. The ends of the septum either side of the defect will be very echogenic if the septum is real (T sign). Small ASDs may only be evident by an increase in the pulmonary outflow detected using Doppler. Colour-flow Doppler allows identification of the defect itself most easily by documenting flow through it.

ASDs form part of the endocardial cushion defects seen in cats, where the atria and ventricles communicate at the site of one large hole.

Performing a Doppler scan

Examination

Start with **right parasternal long-axis view**

Assess:

- interrogate IVS especially on the right ventricular aspect of the aortic root (site of most VSDs)
- Doppler examination of tricuspid flow
- Doppler examination of mitral regurgitation. Although this is not the best view of central jets it can be useful and jets may on occasion be easier to locate in this view than from a left apical view

Rotate transducer to obtain a **right oblique-axis view**

Assess:

Pulmonary outflow (I prefer the left cranial approach but if the acoustic window is poor this is an alternative)

M-mode.

Aortic valve motion (can measure systolic time intervals)

Switch to **left parasternal position**, examine in **long-axis**

Assess: overall size and shape of left ventricle
structure of mitral valve
motion of LV, IVS, mitral valve and aortic valve

Doppler examination of mitral valve and inflow tract and aortic valve and outflow tract

Switch to **sub-costal position**

Assess: structure of interatrial septum and vena cavae
Doppler examination of aortic valve and outflow tract

Adjust the plane of the beam to identify specific lesions as necessary during the examination.

Switch to **left apical position**, examine in **long-axis** to see a **four-chamber (sometimes called 5 chamber) view**

Assess: overall size and shape of the ventricles
structure of mitral, aortic valves
motion of LV, IVS, mitral valve, aortic and tricuspid valve

Doppler examination of mitral valve and inflow tract, tricuspid valve and inflow tract and aortic valve and outflow tract

Switch to short axis view for Doppler of right ventricular outflow, pulmonary valve and pulmonary artery (including left and right branches)